



Diagnosis of Testicular Torsion and Differentiation From Other Pathologies Using Near-Infrared Spectroscopy

Yiğit Ali Üncü, Çağrı Akın Şekerci, Selçuk Yücel, Aslınur Sircan-Kucuksayan, Haydar Kamil Çam, Murat Savaş, Asif Yıldırım, Koray Ağras, Mehmet Baykara, and Murat Canpolat

OBJECTIVE	To develop a near-infrared (NIR) spectroscopy device to diagnose testicular torsion with high sensitivity and specificity. Specifically, we aim to investigate the differentiation between testicular torsion from other pathologies such as orchioepididymitis, varicocele, and hydrocele.
METHODS	Two LEDs with wavelengths of 660 nm and 940 nm were used as light sources in the device. Each wavelength was sent to the testicle successively, and a photodiode detected back-reflected diffuse light. The ratio of the light intensities of 660 nm and 940 nm was used as a diagnostic parameter. A multi-center clinical trial was performed in 5 different hospitals.
RESULTS	In total, 62 patients in urology clinics with acute testicular pain have been recruited for the study. The developed NIR spectroscopy correctly defined all 8 testicular torsion cases. Besides, 3 orchioepididymitis, 1 varicocele, and 3 hydrocele cases were correctly distinguished from testicular torsion. Only 1 hydrocele case was misdiagnosed as torsion. The range of the ratio was between 0.14 and 1.16 overall measurements. The ratio varied between 0.14 and 0.3 for the testicle with torsion. The ratio was between 0.49 and 1.16 for the normal testicle and testicle with other pathologies mentioned above.
CONCLUSION	We have chosen the threshold ratio of 0.4 to differentiate between the normal and torsion testis and diagnosed all the torsion cases among all normal and other pathologies. The developed optical device to diagnose testicular torsion is inexpensive, user-friendly, and works based on objective criteria with high sensitivity and specificity in real time. UROLOGY 173: 159–163, 2023. © 2023 Elsevier Inc.

Testicular torsion is a urological emergency frequently seen in men.¹ Testicular torsion, which may result in the rotation of the testis around the vertical axis and functional tissue loss due to vascular

occlusion, is a condition that requires an urgent approach. Depending on the degree and duration of torsion, complete loss of the testicle may occur due to decreased blood flow and hypoxia in the testicle, just as in other tissues.²⁻³ To maintain viability in ischemic tissues is to provide reperfusion as early as possible; hence, early diagnosis and definitive management are the keys to avoid testicular loss.³⁻⁵

The most commonly used diagnostic modalities in testicular torsion diagnosis are Doppler ultrasonography, radionuclide imaging, and magnetic resonance imaging.³ However, none of them are entirely reliable, fast, and affordable. Evaluation of testicular torsion by most radiological technologies is highly dependent on the urgent availability of the device and the experience of the technician or radiologist.⁶

Radionuclide imaging is a diagnostic method used in the diagnosis of testicular torsion. Radioisotope scintigraphy performed with isotope technetium-99m sodium pertechnetate determines testicular blood flow. It is an invasive diagnostic method requiring intravenous catheter placement and exposure to radiation. Moreover, this modality may not be easily accessible in many centers.

Financial Disclosure: The authors declare that they have no relevant financial interests.

From the Biomedical Optics Research Unit, Department of Biophysics, School of Medicine, Akdeniz University, Antalya, Turkey; the Akdeniz University, Vocational School of Technical Sciences, Department of Biomedical Equipment Technology, Antalya, Turkey; the Department of Urology, Faculty of Medicine, Marmara University, Istanbul, Turkey; the Department of Urology, Acibadem Mehmet Ali Aydınlar University Atakent Hospital, Istanbul, Turkey; the Department of Urology, Marmara University School of Medicine, Istanbul, Turkey; the Department of Biophysics, Faculty of Medicine, Alanya Alaaddin Keykubat University, Antalya, Turkey; the Department of Urology, Antalya Training and Research Hospital, Antalya, Turkey; the Department of Urology, Istanbul Medeniyet University School of Medicine, Ministry of Health Istanbul Göztepe Training and Research Hospital, Istanbul, Turkey; the Department of Urology, Istanbul Medeniyet University School of Medicine, Ministry of Health Istanbul Göztepe Dr. Süleyman Yalçın City Hospital, Istanbul, Turkey; the Urology Clinic, Ministry of Health Ankara Atatürk Training and Research Hospital, Ankara, Turkey; the Private Medical Office, Ankara, Turkey; the Department of Urology, Faculty of Medicine, Akdeniz University, Antalya, Turkey; and the Department of Urology, Lara Anadolu Hospital, Antalya Turkey

Address correspondence to: Murat Canpolat, PhD., Biomedical Optics Research Laboratory, School of Medicine, Department of Biophysics, Akdeniz University, Room F1-18, Konyaaltı, Antalya 07070, Turkey. E-mail: canpolat@akdeniz.edu.tr

Submitted: November 10, 2022, accepted (with revisions): January 2, 2023

This examination appears less optimal, as the test takes a longer time where timely surgery is required.⁷ Doppler ultrasound as a diagnostic tool is one of the essential radiological examinations adopted by many centers to evaluate acute scrotum. The most crucial criterion in diagnosing testicular torsion is a decrease or absence of blood flow to the testicle.^{8,9} The sensitivity of Doppler ultrasound for testicular torsion varies between 70% and 89%.¹⁰ Although it is the most available device in many centers, an experienced operator is required for reliable evaluation.⁶

A fast, affordable, and operator-independent device is desirable to detect testicular torsion. Recently we developed near-infrared (NIR) spectroscopy optical device to detect testicular torsion in rat models.¹¹ In this study, we aimed to test our device's efficacy in detecting testicular torsion in men sent with acute scrotum.

METHODS

Measurement Methods

NIR spectroscopy can be used to calculate the oxygen saturation of hemoglobin in tissue. For some light wavelengths, the measurement uses the variation in the absorption spectra of oxyhemoglobin (Hb) and deoxyhemoglobin (dHb). We performed an in-vivo noninvasive testicular torsion diagnosis using light of 660 nm and 940 nm wavelengths. Lights of the same wavelength are used in pulse oximetry to measure the oxygen saturation of arterial blood. For this reason, it has been proven that the light at the wavelengths does not harm the tissue. Our previous study showed that we could distinguish testicular torsion on an animal model with high sensitivity and specificity by measuring light intensity at 660 and 940 nm wavelengths passing through the testicle. In the study, after the surgical intervention, torsion was applied to the right testicle of the rat by turning it around 720 degrees. The left testicle was used for control. Light intensities at wavelengths of 660 nm and 940 nm, passing through both testicles, respectively, were measured. Then, the measured light intensities ratios were calculated for both the torsion and the control group. We previously showed that we could detect

testicular torsion with 100% sensitivity and specificity with the optical mechanism we developed on the animal model.¹¹

The NIR spectroscopy device developed in the house was used in the study. The device's probe was a light-emitting diode (LED) having wavelengths of 660 nm and 940 nm and a silicon photodiode (OSD-35-LR_D, OSI Optoelectronics, Hawthorne, CA, USA). The device consists of a liquid-crystal display (LCD) and an electronic circuit card to activate the LED at each wavelength sequence and detect back-reflected light from the testicular tissue by the photodiode.¹¹ The measured intensities of each wavelength's diffuse back-reflected light are an average of 64 measurements acquired in 0.4 s. The ratio of the measured intensities is presented on the LCD. The principle of the device is based on the detection of increasing deoxyhemoglobin concentration in the torsion testicle. At 660 nm, the absorption of deoxyhemoglobin is greater than that of oxyhemoglobin and vice versa at wavelength 940 nm.¹²

Therefore, the ratio to be used as a diagnostic parameter is

$$R = \frac{I_{660}}{I_{940}} \frac{1}{K}. \quad (1)$$

I_{660} and I_{940} are the light intensities measured on the testis, and K is the calibration constant defined as the ratio of powers of the incident light of wavelengths 660 nm and 940 nm. In the case of testicular torsion concentration of deoxyhemoglobin increases, the absorption of light at 660 nm wavelength increases, I_{660} becomes smaller, and the diagnostic parameter R becomes smaller. This is because the ratio, R , is inversely proportional to deoxyhemoglobin concentration. Therefore, increased deoxyhemoglobin concentration in testicular torsion results in a decreased ratio R due to high deoxyhemoglobin absorption at 660 nm.

LED emits the light into the testicular tissue, and the photodiode detects the diffuse back-reflected light from the testis. The measuring and set button on the probe was pressed, and the measurement was taken approximately 3 s after the probe was lightly touched on the testicle. Then the exact measurement was taken on the normal testicle. The measurement results and the ratio R presented on the LCD Display were entered in the patient follow-up form for torsion and intact testicles. The device prototype is shown in Figure 1.

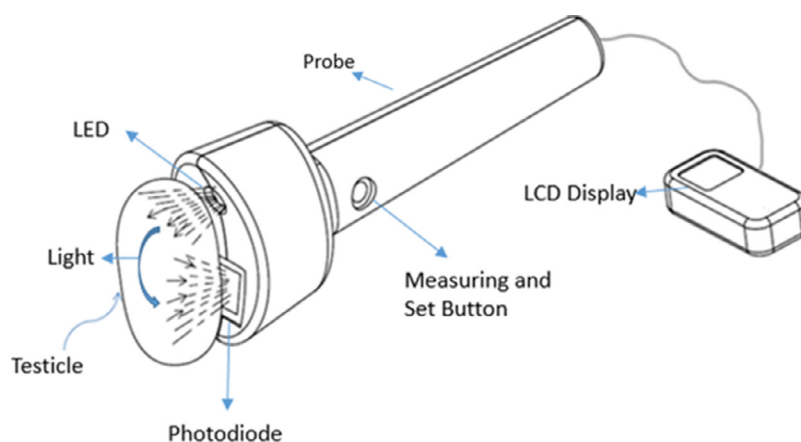


Figure 1. The optical probe for real-time measurements; schematic illustration of the light output from the LED into the testicle and back-reflection from the testis; the photodiode detects the diffuse back-reflected light for both wavelengths. (Color version available online.)

The Instructions for the use of the Optical Device

The device probe is elliptical, and the long axis of the probe is lightly touched to the testicle so that it grasps the testicle, and then the measurement button on the box is pressed. The parameter on the electronic display on the box is read and recorded in the patient follow-up form after the measurement is finished. The probe surface was sterilized by wiping the alcohol with a cloth before acquiring the data from the next patient.

During the measurements, the light of 660 nm wavelength is sent 10 times in 20 ms intervals for 80 ms within 1 second, and the light intensity entering and leaving the testicle is measured. The embedded software averaged the measurements in the electronic hardware. The same process is done in light with a wavelength of 980 nm. The ratios of the measured average light intensities are then calculated in the embedded software and displayed on the LCD.

Clinical Study

The clinical study was conducted at Akdeniz University Hospital, Antalya Education and Research Hospital, Acibadem University Hospital, and Marmara University Hospital. Measurements were taken from the patients who presented to the clinic at any time of day with acute testicular pain and volunteered to participate in the study. The protocol of the study on patients;

- First, informed consent was obtained from the patient shortly after being presented to the emergency department or urology outpatient clinic without causing a delay in surgical exploration. Then, optical measurements were acquired from suspected testicular torsion.
- Routine diagnostics and treatment procedures were performed on the patients without considering the outcomes of the optical measurements.
- The diagnostic results were compared with the optical results obtained.
- The threshold value of the parameter (the ratio of light intensities back reflected from the testis) to be used to distinguish testicular torsion from other pathologies was determined.

Acute scrotum (pain and/or swelling) cases of all ages who were consulted to emergency and urology clinics in the first 6 hours of symptoms underwent physical examination and

urgent Doppler scrotal ultrasonography. During the physical examination, NIR spectroscopy optical measurement is performed for both testes only in cases who agreed to participate with informed consent from the patient or caregivers in this study. All Doppler ultrasonography-diagnosed testicular torsions underwent urgent surgical exploration. The value of the NIR spectroscopy parameter (the ratio of light intensities reflected from the testicle) was determined, recorded, and correlated with clinical, radiological, and surgical findings.

The control group was boys and men with no scrotal complaints and routine physical examination. All control cases were measured with NIR spectroscopy for both tests and recorded. NIR spectroscopy results were compared in the study's control and acute scrotum cases according to the clinical, radiologic, and surgical findings. Hypothesis tests compare the means of a given quantitative variable with 2 independent groups. If the normal distribution condition is satisfied, the independent samples *t*-test is used. However, when the data is not normally distributed, the Mann–Whitney *U* test is applied to compare the means of 2 independent groups.¹³⁻¹⁴ Therefore, we used the Mann–Whitney *U* test to compare our study's means of 2 independent groups.

RESULTS

The mean age of the control group (50 boys and men) was 24.5 years (range: 6-34 years). 16 boys and men presented with acute scrotum were enrolled in the study. Their mean age was 18.2 years (range: 6-33 years). Of those cases, 8 (mean age: 20.75, range: 16-28 years) were found to have testicular torsion and underwent surgical treatment, and other 8 (mean age: 15.7, range: 4-33 years) were found to have different pathologies: 4 hydroceles, 1 varicocele, and 3 orchidoepididymitis. No Doppler ultrasonography confirmed the case was untorsed, and none of the cases with no torsion developed torsion in a month of follow-up.

Figure 2 represents the measurement results taken from the right and left testicles of the subjects in the control group. The mean of the measurements taken from the right testicles of the subjects in the control group was determined as 0.86 ± 0.08 . The values measured from the right testicles of the subjects fit the normal distribution. The mean of the measurements taken from the left testicles was determined as 0.85 ± 0.09 . The values measured from the left testes of the subjects fit the normal distribution. There is no significant difference from person to person

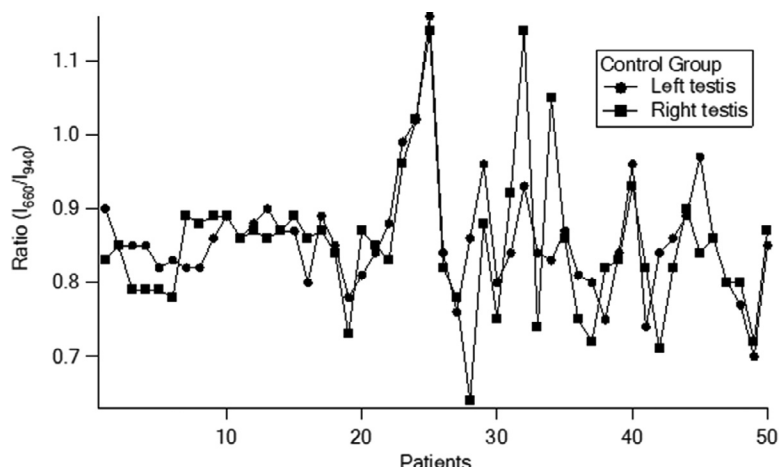


Figure 2. Measurement results are taken from the right and left testicles of the subjects in the control group.

Table 1. Measurement results taken from torsion and normal testicles of patients diagnosed with testicular torsion.

Diagnosis	Right Testicles	Left Testicles	Age
1	1.06	0.3	16
2	0.25	0.97	18
3	0.90	0.23	25
4	1.25	0.26	17
5	0.14	0.89	23
6	0.14	0.89	28
7	0.14	0.75	21
8	0.23	0.65	18

in the control group. Only 1 case with a left hydrocele showed bilateral low measurements but Doppler ultrasonography showed normal vascularization on both testes and did not undergo surgical exploration.

Testicular torsion has been identified using the ratio of the average intensities of the transmitted light at the 2 wavelengths of 660 nm and 940 nm. Optical measurements have been taken from both testicles in the control group to demonstrate the consistency and reproducibility of the measurements. The mean values and standard deviations of the left and right testicular diagnostic parameters show no statistically significant differences between the measurements taken from the right and left testicles of the subjects in the control group ($P = .885$).

The measurement results obtained from the torsion and normal contralateral testis of the patients diagnosed with testicular torsion in the torsion group are shown in Table 1. The mean of the measurements taken from the testis with torsion was determined as 0.21 ± 0.07 . The standard of the measures taken from the normal testicles of the same people was determined as 0.96 ± 0.15 .

A significant difference in the ratio between the measurements taken from the testes with torsion and the contralateral normal testes from the patients in the torsion groups, using the Mann–Whitney U test ($P < .0001$). When the control and torsion groups were compared, the difference in the ratio between the torsion and the control groups, using Mann–Whitney U test ($P < .0001$).

The measurement results obtained from the right and left testicles of patients diagnosed with a disease other than torsion are shown in Table 2. It is seen that the measurement values taken on the testes with varicocele, orchidoepididymitis, and hydrocele are close to the normal testicle. This represents that the above-mentioned pathologies of the optic system can be distinguished from testicular torsion. However, in 1 hydrocele case,

Table 2. Measurement results taken from the right and left testicles of patients diagnosed with diseases other than torsion.

Diagnosis	Right Testicles	Left Testicles	Age
Left varicocele	0.81	0.73	10
Left hydrocele	0.85	0.87	4
Right orchidoepididymitis	0.76	0.78	8
Right orchidoepididymitis	0.57	0.63	32
Left orchidoepididymitis	0.71	0.78	9
Left hydrocele	0.47	0.54	14
Left hydrocele	0.49	0.97	33
Left hydrocele	0.25	0.19	28

the measurement values of both testes are low, which may result in a human-source measurement error.

CONCLUSION

It is desirable to have an affordable and easily used device for clinicians in emergency settings to detect testicular torsion quickly during the physical examination. We presented our easy-to-use and affordable NIR spectroscopy device that could detect testicular torsion in animal models. In this study, we report our findings of this optical device in acute scrotum cases and healthy control subjects of all ages. It is important to note that each measurement was done during the physical examination and took only a few seconds, even by physicians without experience with the device.

The findings of our device have not changed the approach to the acute scrotum case; urgent Doppler ultrasonography was performed in each to detect testicular torsion. Only Doppler ultrasonography confirmed torsion cases were surgically explored and treated accordingly. However, NIR spectroscopy successfully differentiates all torsions before the Doppler ultrasonography in each case. NIR spectroscopy also can differentiate testicular torsion from other scrotal pathologies such as orchitis, hydrocele, and varicocele.

To summarize, there is no statistically significant difference between the measurements taken from the right and left testicles of the subjects in the control group ($P = .885$). However, there is a statistically significant difference between the measurements taken from the testicular torsion and the measurements taken from the normal testicle from the patients in the torsion group ($P < .0001$). When the control and torsion groups were compared, there was a statistically significant difference between the measurement values in the control group and the measurements obtained from the testicle with torsion ($P < .0001$), as seen in Table 1. As seen in Table 2, the measurements obtained in hydrocele, orchidoepididymitis, and varicocele differ from those acquired from normal testicles except for only 1 hydrocele case. We guess that it is a human-sourced error where good contact of the probe with the testicle is not achieved.

Several studies used spectroscopy to diagnose testicular torsion in literature, some of them were conducted on an animal model,^{11,15,16} and some were conducted in clinics.¹⁷⁻²¹ Burgu et al¹⁷ used NIR spectroscopy in a pilot study to evaluate acute adult scrotum by measuring testicular oxygen saturation (StO_2). The mean value of the StO_2 of unaffected testes was 69.03%, and in the torsion case, the StO_2 level lowered by 11.5 units more than the contralateral unaffected testis. They successfully differentiated testicular torsion from unaffected testis.

In a case study, the tissue saturation index of the right and left spermatic cord was measured, and a significant reduction of oxygen saturation was found in the spermatic cord with testicular torsion.²¹ Schlomer et al²⁰ conducted a NIR spectroscopy study to diagnose testicular torsion in the pediatric acute scrotum group of 121 patients with 36

testicular torsions and showed that NIR spectroscopy successfully discriminates torsion and non-torsion testis. However, none of the above studies investigated NIR spectroscopy's ability to differentiate different testicular pathologies, such as orchidoepididymitis, varicocele, and hydrocele, from testicular torsion. In the presented study, we have successfully determined 5 pathologies from testicular torsion for a patient group under age 15 and 2 patients above 30. In 1 patient, the measurements result from the hydrocele, and normal testis was below the threshold value of testicular torsion. It may be due to an inappropriate measurement. These studies show that spectroscopy systems operate with high sensitivity and specificity. Schoenfeld et al¹⁹ reported no significant difference between NIR spectroscopy measurements between normal and torted testis. The authors stated that this might be related to the device or patient heterogeneity. The present study used only 2 wavelengths of light and measured the intensity of light at each wavelength that interacted with the testicle. Thus, we have represented that the cost of the system is much lower and has the potential to be used in clinics.

The study has some limitations; patients were not compared according to the duration of symptoms. Another point is age heterogeneity. In pediatric patients, we did not evaluate the results of NIR spectroscopy in terms of Tanner stages. Patients with and without scrotal edema were not compared. Postoperative NIR spectroscopy measurement was also not made.

The presented clinical trial showed that the dual-wavelength optical device successfully diagnosed testicular torsions in real-time and noninvasively. Besides, the optical device also differentiated between testicular torsion and other pathologies such as varicocele, hydrocele, and orchidoepididymitis. Furthermore, the dual-wavelength optical device employed in the clinical trial is user-friendly, inexpensive, and works based on objective criteria and may require only brief training.

Acknowledgments. The authors thank the Scientific and Technological Research Council of Turkey (TÜBİTAK), Project No: 113S071.

References

1. Barada JH, Weingarten JL, Cromie WJ. Testicular salvage and age-related delay in the presentation of testicular torsion. *J Urol.* 1989;142:746–748.
2. Nagler HM, White RD. The effect of testicular torsion on the contralateral testicle. *J Urol.* 1982;128:1343–1348.

3. Ringdahl E, Teague L. Testicular torsion. *Am Fam Physician.* 2006;74:1739–1743.
4. Akgur FM, Kilinc K, Aktug T. Reperfusion injury after detorsion of unilateral testicular torsion. *Urol Res.* 1993;21:395–399.
5. Desai C, Raghuvanshi K, Panesar H, Murali V. Importance of touch: managing testicular torsion in a 28-year-old with Duchenne muscular dystrophy. *Cureus.* 2022;14:e22775.
6. Laher A, Swart M, Honiball J, Perera M, Lawrentschuk N, Adam A. Near-infrared spectroscopy in the diagnosis of testicular torsion: valuable modality or waste of valuable time? A systematic review. *ANZ J Surg.* 2020;90:708–714.
7. Middleton WD, Siegel BA, Melson GL, Yates CK, Andriole GL. Acute scrotal disorders: prospective comparison of color Doppler us and testicular scintigraphy. *Radiology.* 1990;177:177–181.
8. Arce JD, Cortes M, Vargas JC. Sonographic diagnosis of acute spermatic cord torsion—rotation of the cord: a key to the diagnosis. *Pediatr Radiol.* 2002;32:485–491.
9. Baud C, Veyrac C, Couture A, Ferran JL. Spiral twist of the spermatic cord: a reliable sign of testicular torsion. *Pediatr Radiol.* 1998;28:950–954.
10. Dubinsky TJ, Chen PB, Maklad N. Color-flow and power Doppler imaging of the testes. *World J Urol.* 1998;16:35–40.
11. Canpolat M, Yucel S, Sircan-Kucuksayan A, Kol A, Kazanci HO, Denkceken T. Diagnosis of testicular torsion by measuring attenuation of dual wavelengths in transmission geometry across the testicle: an experimental study in a rat model. *Urology.* 2012;79:966.e9-12.
12. Prahl, S 2007 Tabulated molar extinction coefficient for hemoglobin in water. Available at: <http://omlc.ogi.edu/spectra/hemoglobin/summary.html>. 23 June 2022.
13. Hollander M, Wolfe DA. *Nonparametric Statistical Methods.* 2nd ed. New York, NY: Wiley; 1999.
14. Lehmann EL. *Nonparametrics: Statistical Methods Based On Ranks.* New York, NY: Springer; 2006.
15. Aydogdu O, Burgu B, Gocun PU, et al. Near infrared spectroscopy to diagnose experimental testicular torsion: comparison with Doppler ultrasound and immunohistochemical correlation of tissue oxygenation and viability. *J Urol.* 2012;187:744–750.
16. Capraro GA, Mader TJ, Coughlin BF, et al. Feasibility of using near-infrared spectroscopy to diagnose testicular torsion: an experimental study in sheep. *Ann Emerg Med.* 2007;49:520–525.
17. Burgu B, Aydogdu O, Huang R, Soygur T, Yaman O, Baker L. Pilot feasibility study of transscrotal near infrared spectroscopy in the evaluation of adult acute scrotum. *J Urol.* 2013;190:124–129.
18. Laher A, Ragavan S, Mehta P, Adam A. Testicular torsion in the emergency room: a review of detection and management strategies. *Open Access Emerg Med.* 2020;12:237–246.
19. Schoenfeld EM, Capraro GA, Blank FS, Couste RA, Visintainer PF. Near-infrared spectroscopy assessment of tissue saturation of oxygen in torted and healthy testes. *Acad Emerg Med.* 2013;20:1080–1083.
20. Schlomer BJ, Keays MA, Grimsby GM, et al. Trans-scrotal near-infrared spectroscopy as a diagnostic test for testicle torsion in pediatric acute scrotum: a prospective comparison to gold standard diagnostic test study. *J Urol.* 2017;198:694–701.
21. Shadgan B, Fareghi M, Stothers L, Macnab A, Kajbafzadeh AM. Diagnosis of testicular torsion using near infrared spectroscopy: a novel diagnostic approach. *Can Urol Assoc J.* 2014;8:E249–E252.