

Correction of persistent crowding in the lower anterior region: A case report

Leyla Cime Akbaydogan¹, Zeliha Muge Baka², Esra Ulusoy Mutluol²

¹ Alanya Alaaddin Keykubat University, Faculty of Dentistry, Department of Orthodontics, Alanya, Turkey

² Selcuk University, Faculty of Dentistry, Department of Orthodontics, Konya, Turkey

Abstract

Aim: This case report demonstrates the application of piezocision in correcting persistent crowding in the lower anterior region of dental arch.

Methodology: A female aged 14 years and 3 months presented to the Selçuk University, Faculty of Dentistry, Department of Orthodontics due to esthetic complaints. Clinical and radiological examination revealed crowding in the upper and lower dental arches as well as skeletal and dental Class I malocclusion. First, bonding and arch wire were applied to the patient's upper jaw. The patient then had check-up appointments at 4-week intervals. In the second session, bonding was applied to the lower jaw. As the leveling was completed in the upper jaw, thicker arch wires were used. However, 4 months after the bonding of the lower anterior region, leveling did not occur. Consequently, piezocision was applied to the lower anterior region. Then, two applications of 0.014" and 0.016" Ni-Ti wire were carried out, respectively. After the completion of the leveling, intrusion was provided with the utility arch placed on the lower incisor brackets. Orthodontic treatment was concluded with the use of Ni-Ti and steel angle wires.

Conclusion: Efficient leveling was achieved in the lower anterior region with piezocision applications.

Correspondence:

Uzm. Dt. Esra ULUSOY MUTLUOL
Selcuk University, Faculty of
Dentistry, Department of
Orthodontics, Konya, Turkey.
E-mail: mutluolesra@hotmail.com

Received: 11 March 2021

Accepted: 15 May 2021

Access Online



DOI:

10.5577/intdentres.2021.vol11.suppl1.45

Keywords: mandibular anterior crowding, piezocision, Class I malocclusion

How to cite this article Cime Akbaydogan L, Baka ZM, Ulusoy Mutluol E. Correction of persistent crowding in the lower anterior region: A case report. Int Dent Res 2021;11(Suppl.1):303-7. <https://doi.org/10.5577/intdentres.2021.vol11.suppl1.45>

Introduction

Prolonged orthodontic treatment duration is cited as the main reason for patients' tendency to avoid treatment. The duration of the treatment may result in patients either abandoning the treatment or turning to alternative therapies that result in a shorter treatment period. Increase in orthodontic treatment time is associated with periodontal problems, caries formation, and external root resorption. For all these reasons, studies are carried out to shorten the duration

of treatment by accelerating orthodontic tooth movement (1-6).

In the literature, electric current (7), magnet (8), dental distraction (9), laser (10), alveolar surgery of the interseptal bone (11), corticotomy (12), bone incision (13), corticision (14), ultrasound (15), micro-osteoperforation (4), piezocision (16), and platelet-rich plasma (PRP) and platelet-rich fibrin (PRF) injection (17) methods are presented. The aim of this case report is to demonstrate the piezocision application for correcting crowding in the lower anterior region.

Case Report

A female patient aged 14 years and 3 months presented to the Selçuk University, Faculty of Dentistry, Department of Orthodontics with esthetic complaints. An assessment of the patient's medical history revealed no systemic or dental disease that could constitute an obstacle for orthodontic treatment. Clinical examination of the patient revealed a flat profile, a bilateral angle Class I canine and molar relationship, a 2-mm overjet, and a 4-mm overbite.

The upper midline was in the correct position, whereas the lower midline deviated 2 mm to the left. The arch length discrepancy was -4 mm in the upper jaw and -2.5 mm in the lower jaw. Tooth number 13 was in the high vestibule (Fig. 1). No pathological findings were found in the panoramic x-ray evaluation, and it was determined that the patient had all permanent teeth except third molars. Cephalometric analysis revealed that the patient had a skeletal Class I (SNA: 83.9°, SNB: 80.6°, ANB: 3.3°) malocclusion and horizontal growth pattern (SN-GoGn: 18) (Fig.2).

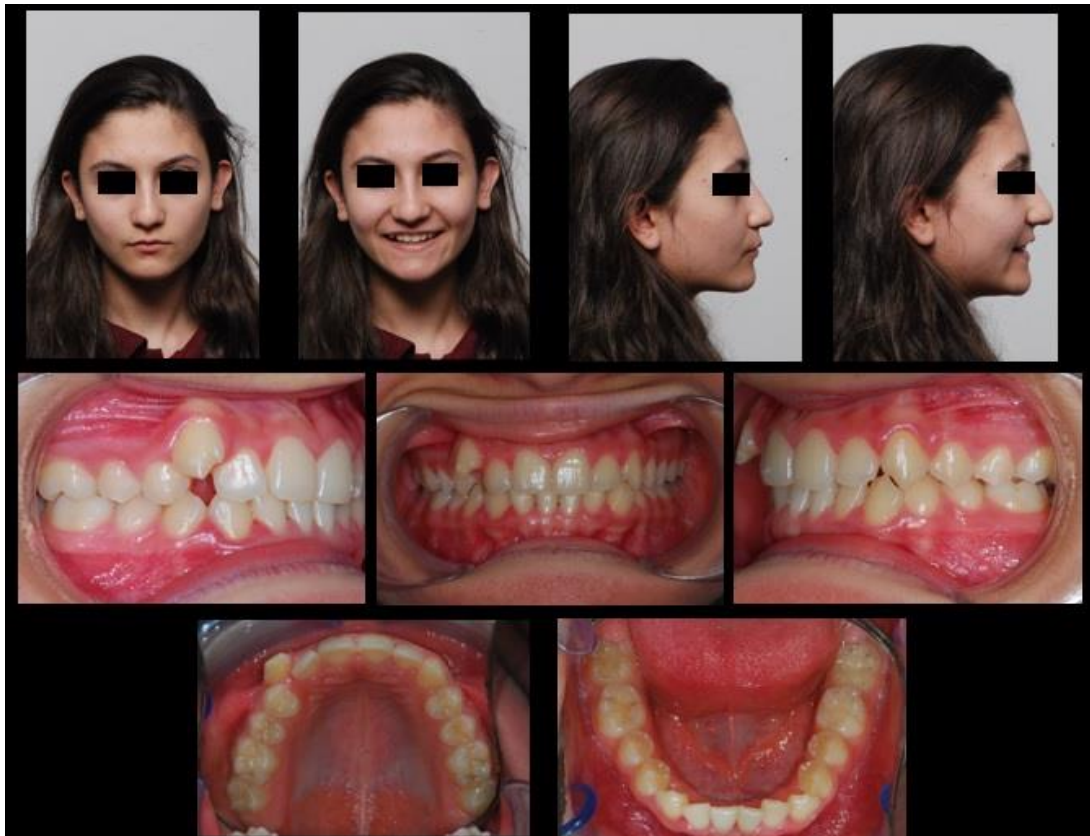


Figure 1. Pre-treatment images of the patient

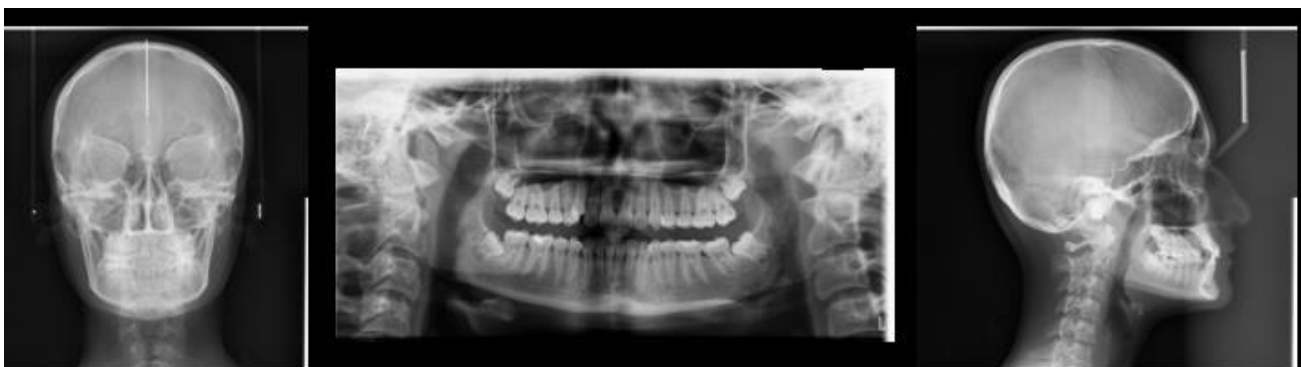

Figure 2. Pre-treatment X-rays of the patient

Fixed orthodontic treatment of the patient without extraction was selected. Bonding was performed with brackets (Discovery™ Smart, Dentaaurum, MBT, Ispringen, Germany) with a 0.022"-slot MBT system (System McLaughlin-Bennett-Trevisi * 22). First, the upper jaw was bonded, and a 0.014" Ni-Ti arch wire was attached. Check-up visits were scheduled at 4-week intervals. In the second session, bonding of the lower jaw was performed, and a 0.014" Ni-Ti arch wire was applied to the lower jaw, whereas a 0.016" Ni-Ti wire was applied to the upper jaw.

In monthly controls, 0.016" x 0.016" and 0.016" x 0.022" Ni-Ti arch wires were applied to the upper jaw, respectively. However, thicker arch wires could not be used in the lower jaw due to the lack of leveling. Because deformation of the arch wire may adversely affect the leveling, the 0.014" Ni-Ti arch wire was renewed in the third session. It was observed that the leveling in the lower jaw was not complete at the end of a total period of 4 months. As a result, piezocision was applied to the lower anterior region (Fig. 3).

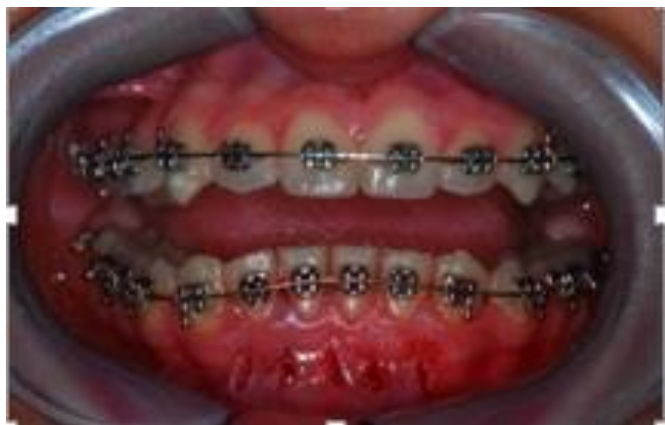

Figure 3. Piezocision application on the lower anterior region

Crown root extension was examined on panoramic radiography before the procedure. The patient was instructed to rinse with a chlorhexidine-containing mouthwash for 30 seconds. Piezocision was performed in accordance with the description of Dibart et al. (18). The lower anterior region was anesthetized via local infiltration anesthesia. Piezocision was performed in the area adjacent to the roots of the teeth between the canines. Small vertical incisions were made on the adherent gingiva or alveolar mucosa 2-3 mm below the gingiva with a no.15 scalpel. This procedure approach aimed to preserve the integrity of the interdental papilla and to ensure that the length of the incision lines was sufficient to allow the piezotomy blade to be inserted. Then, using saline for cooling, 3 mm-deep incisions were made via rhythmic movements without pressure. Piezocision was applied using the Piezon Master Surgery™ (EMS, Nyon, Switzerland) device in surgery mode. The depth adjustment was made with the marking lines performed through the saw-shaped tip of SL1, which can effectively cut cortical bone. After the piezocision was completed, no subsequent sutures were performed on the incision lines. The patient was prescribed a chlorhexidine-containing mouthwash to rinse with twice a day for a week. The

patient was instructed not to take anti-inflammatory analgesic drugs, consume spicy food, or brush the piezocision area. The 0.014" arch wire was retained for 2 sessions, and afterward, the leveling process was continued with 0.016" arch wire. At this stage, 0.017" x 0.025" Ni-Ti as well as 0.017" x 0.025" and 0.018" x 0.025" steel arch wires were attached to the upper jaw, respectively. In order to obtain intrusion following the leveling of round wires, the 0.016" x 0.016" blue elgiloy utility arch was applied to the lower jaw, bypassing the canine and premolar teeth, it was placed in the bracket of the four incisors. In order to prevent incisor protrusion and the anterior movement of the wire, the arch wire was bent at the distal of the molar teeth. Adequate intrusion was achieved at the end of 3 months. 0.016" x 0.016" and 0.016" x 0.022" Ni-Ti arch wires and 0.016" x 0.022", 0.017" x 0.025" steel arch wires were attached to the lower jaw, respectively. The total treatment period of the patient lasted 18 months. Figures 4 and 5 present post-treatment images and x-rays of the patient. Lingual retainer and Hawley appliance were used to maintain the results of the treatment. Reinforcement apparatus were used for a total of two years and gradually discontinued.

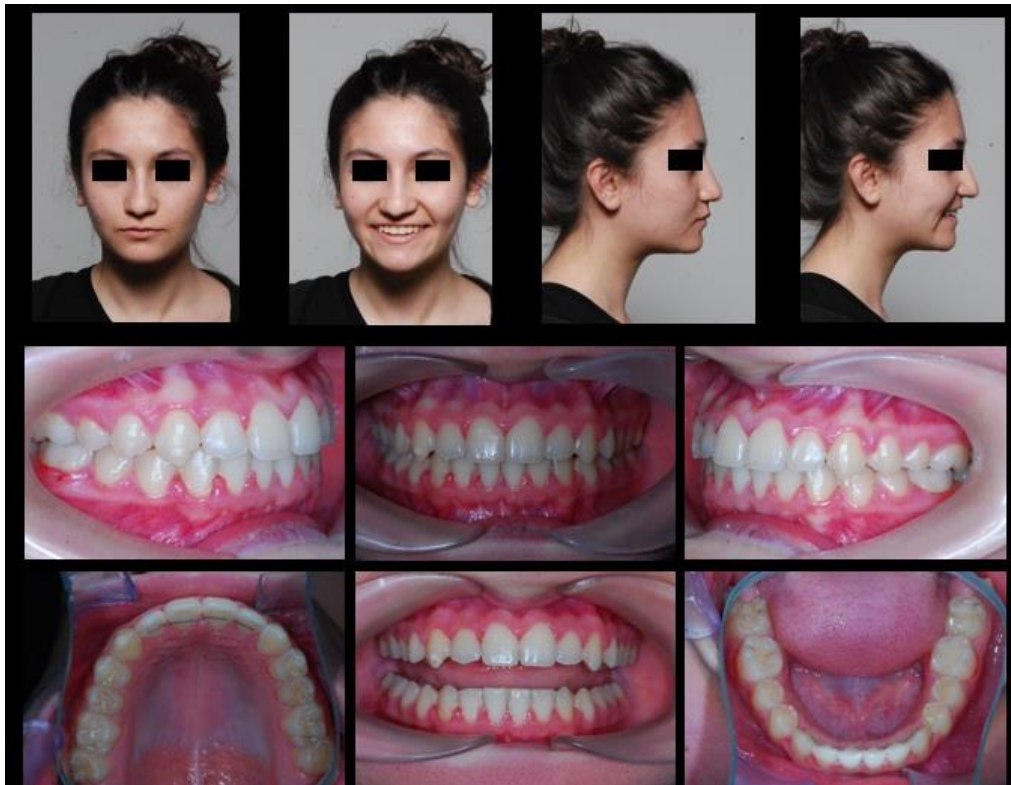


Figure 4. Post-treatment images of the patient

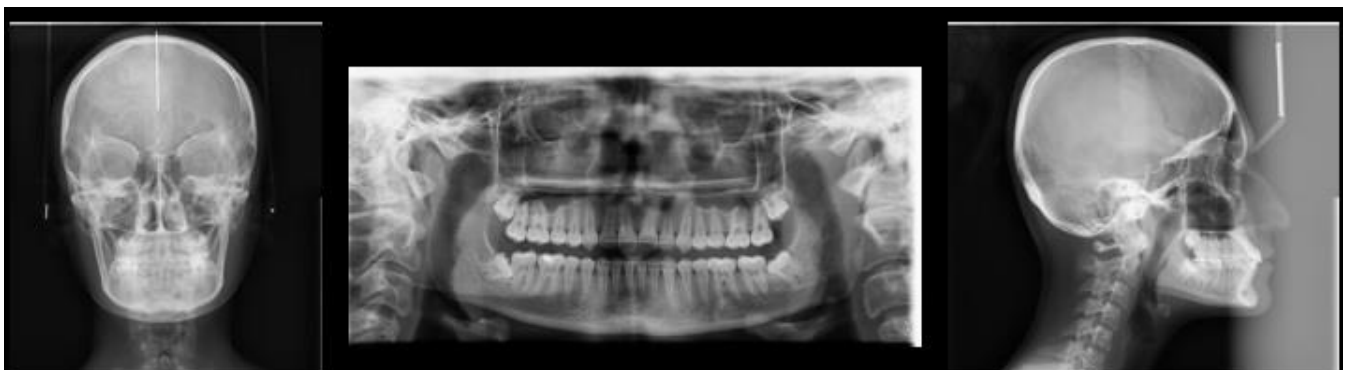

Figure 5. Post-treatment X-rays of the patient

Discussion

The main factor that determines orthodontic tooth movement rate and treatment duration is the biological response of the teeth to orthodontic force. The basis of tooth movement is bone resorption that occurs as a result of osteoclastic activity (4). In this case, piezocision was preferred because it is a minimally invasive procedure and provides ease of application (18).

Uribe et al. stated in their study that piezocision has no effect on orthodontic tooth movement in the leveling of the lower anterior teeth (19). Charavet et al. reported that piezocision applications shortened the duration of clinical orthodontic treatment by 43% (20).

Conclusions

In this case report, piezocision was applied as an alternative to the patient whose leveling was delayed in the lower anterior region following traditional orthodontic treatment methods.

Finally, tooth number 13 was migrated to its optimum position on the arch. Leveling was successfully performed with piezocision application in the lower incisors. Intrusion was obtained in the lower incisors with the help of utility arches. An esthetic and functional occlusion has been provided.

In the presented case, piezocision application produced beneficial results regarding tooth movement and an increase in the rate of tooth movement was observed. All in all, piezocision technique is recommended for accelerated orthodontic treatment.

Acknowledgments: This study was presented as a full-text oral presentation at the 1st International Dental Research and Health Sciences Congress held between 20-22 May 2021.

Patient Consent for Publication: Written informed consent was obtained from the patient.

Peer-review: Externally peer-reviewed.

Author Contributions: Conception - L.C.A.; Design - Z.M.B.; Supervision - E.U.M.; Materials - L.C.A.; Data Collection and/or Processing - Z.M.B.; Analysis and/or Interpretation - E.U.M.; Literature Review - L.C.A.; Writer - E.U.M.; Critical Review - Z.M.B.

Conflict of Interest: No conflict of interest was declared by the authors.

Financial Disclosure: The authors declared that this study has received no financial support.

References

1. Fink DF, Smith RJ. The duration of orthodontic treatment. *Am J Orthod Dentofacial Orthop* 1992; 102(1), 45-51. ([Crossref](#))
2. Roykó A, Dénes Z, Razouk G. The relationship between the length of orthodontic treatment and patient compliance. *Fogorv Sz* 1999; 92(3), 79-86.
3. Pandis N, Nasika M, Polychronopoulou A, Eliades T. External apical root resorption in patients treated with conventional and self-ligating brackets. *Am J Orthod Dentofacial Orthop* 2008; 134(5), 646-51. ([Crossref](#))
4. Alikhani M, Raptis M, Zoldan B, Sangsuwon C, Lee YB, Alyami B, Corpodian C, Barrera LM, Alansari S, Khoo E, Teixeira. Effect of micro-osteoperforations on the rate of tooth movement. *Am J Orthod Dentofacial Orthop*, 2013;144(5), 639-48 ([Crossref](#))
5. Maheshwari S, Verma SK, Tariq M, Gaur A. Rapid Orthodontics- A critical review. *J University J Dent Scie* 2015; 1, 1, 35-8.
6. Jing D, Xiao J, Li X, Li Y, Zhao Z. The effectiveness of vibrational stimulus to accelerate orthodontic tooth movement: a systematic review. *BMC Oral Health* 2017; 17(1), 143. ([Crossref](#))
7. Davidovitch Z, Finkelson MD, Steigman S, Shanfeld JL, Montgomery PC, Korostoff E. Electric currents, bone remodeling, and orthodontic tooth movement: I. The effect of electric currents on periodontal cyclic nucleotides. *Am J Orthod* 1980; 77(1), 14-32. ([Crossref](#))
8. Darendeliler MA, Sinclair PM, Kusy RP. The effects of samarium-cobalt magnets and pulsed electromagnetic fields on tooth movement. *Am J Orthod Dentofacial Orthop* 1995; 107(6), 578-88. ([Crossref](#))
9. Liou EJ, Huang CS. Rapid canine retraction through distraction of the periodontal ligament. *Am J Orthod Dentofacial Orthop* 1998; 114(4), 372-82. ([Crossref](#))
10. Kawasaki K, Shimizu N. Effects of low-energy laser irradiation on bone remodeling during experimental tooth movement in rats. *Lasers in Surgery and Medicine: The Official Journal of the American Society for Laser Medicine and Surgery* 2000; 282-91 ([Crossref](#))
11. Ren A, Lv T, Kang N, Zhao B, Chen Y, Bai D. Rapid orthodontic tooth movement aided by alveolar surgery in beagles. *Am J Orthod Dentofacial Orthop* 2007; 131(2):160(1),10. ([Crossref](#))
12. Moon CH, Wee JU, Lee HS. Intrusion of overerupted molars by corticotomy and orthodontic skeletal anchorage. *Angle Orthod* 2007; 77(6), 1119-25. ([Crossref](#))
13. Sebaoun JD, Ferguson DJ, Wilcko MT, Wilcko WM. Alveolar osteotomy and rapid orthodontic treatments. *L'Orthodontie francaise* 2007; 78(3), 217-25. ([Crossref](#))
14. Kim SJ, Park YG, Kang SG. Effects of Corticision on paradental remodeling in orthodontic tooth movement. *Angle Orthod* 2009; 79(2), 284-91. ([Crossref](#))
15. El-Bialy T, Lam B, Aldaghreer S, Sloan AJ. The effect of low intensity pulsed ultrasound in a 3D ex vivo orthodontic model. *J Dent* 2011; 39(10), 693-99. ([Crossref](#))
16. Dibart S, Keser El. Piezocision: Minimally invasive periodontally accelerated orthodontic tooth movement procedure. In. *Orthodontically Driven Corticotomy: Tissue Engineering to Enhance Orthodontic and Multidisciplinary Treatment*. Ed: F Brugnami, A Caiazzo, first edition, Oxford, John Wiley & Sons Inc, 2014. p. 119-44. ([Crossref](#))
17. Liou EJ. The development of submucosal injection of platelet rich plasma for accelerating orthodontic tooth movement and preserving pressure side alveolar bone. *APOS Trends in Orthodontics* 2016; 6, 1, 5. ([Crossref](#))
18. Dibart S, Sebaoun JD, Surmenian J. Piezocision: a minimally invasive, periodontally accelerated orthodontic tooth movement procedure. *Compend Contin Educ Dent* 2009; 30(6), 342-44, 346, 348-50.
19. Uribe F, Davoody L, Mehr R, Jayaratne YS, Almas K, Sobue T, Allareddy V, Nanda R. Efficiency of piezotome-corticision assisted orthodontics in alleviating mandibular anterior crowding—a randomized clinical trial. *Eur J Orthod* 2017; 39(6), 595-600. ([Crossref](#))
20. Charavet C, Lecloux G, Bruwier A, Rompen E, Maes N, Limme M, Lambert F. Localized Piezoelectric Alveolar Decortication for Orthodontic Treatment in Adults: A Randomized Controlled Trial. *J Dent Res* 2016; 95(9), 1003-9. ([Crossref](#))