

Laryngopharyngeal lesion awareness of physicians performing upper gastrointestinal endoscopy: Survey study

 Gözde Orhan Kubat,¹  Mehmet Kubat,²  Mahmut Demirtaş,³  Ozan Bağış Özgürsoy⁴

¹Department of Otolaryngology, Alanya Alaaddin Keykubat University Faculty of Medicine, Antalya, Türkiye

²Department of General Surgery, Alanya Training and Research Hospital, Antalya, Türkiye

³Department of Otolaryngology, Muğla Sıtkı Koçman University Faculty of Medicine, Muğla, Türkiye

⁴Department of Otolaryngology, Ankara University Faculty of Medicine, Ankara, Türkiye

ABSTRACT

Introduction: Early diagnosis of cancers in the laryngeal and pharyngeal (LF) region is important for minimally invasive treatment and prolongation of survival. In the practice of otolaryngology diseases, hypopharyngeal cancers are mostly diagnosed in the late period. The aim of this study is to evaluate the approaches of gastroenterology and general surgery specialists to LF region lesions during upper gastrointestinal (UGI) endoscopic procedures.

Materials and Methods: Endoscopist physicians who agreed to participate in our study and performed UGI endoscopy were asked to fill out the online questionnaire and the results were evaluated. Survey results; It is based on demographic information, professional experience and characteristics of the procedure, endoscopy evaluation criteria, whether anatomical regions are evaluated and laryngeal and hypopharyngeal region lesions can be defined.

Results: It was observed that 88% of the 100 participants who participated in the survey evaluated the LF region, and 71% encountered lesions in the hypopharynx, 62% with lesions obstructing the esophagus entrance, and 52% with laryngeal lesions. It was determined that 23.7% of the physicians who encountered hypopharyngeal lesions and 11.5% of the physicians who encountered laryngeal lesions took biopsies from the lesions in these regions. As the endoscopic experience increased, the identifiability of the lesions increased statistically significantly ($p < 0.05$). The identifiability of the lesions was found to be statistically significantly lower in the group who thought that the education received during their residency was insufficient ($p < 0.05$).

Conclusion: With the routine evaluation of LF structures during endoscopy of the UGI, it is possible to diagnose lesions in this region at an early stage. In this age, where minimally invasive and organ-preserving endoscopic treatments are at the forefront, routine evaluation of LF regions should be included in the UGI endoscopy training required to increase the accuracy of diagnostic approaches. To increase the early diagnosis rate, endoscopists should be informed about the examination of anatomical regions in detail, and they should be encouraged to take biopsies in suspicious cases. In this period, the percentage of biopsy should be increased by performing simultaneous otolaryngology consultation.

Keywords: Endoscopy, Hypopharyngeal neoplasia, Laryngeal neoplasia, Surgery, Upper gastrointestinal tract



Received: 13.04.2022 Accepted: 22.05.2022

Correspondence: Gözde Orhan Kubat, M.D., Department of Otolaryngology, Alanya Alaaddin Keykubat University Faculty of Medicine, Antalya, Türkiye

e-mail: gozde.orhan@alanya.edu.tr



This work is licensed under a Creative Commons Attribution-NonCommercial 4.0 International License.

Introduction

The number of upper and lower gastrointestinal endoscopic procedures has increased since cancer screening programs have started to be widely used.^[1] It was estimated that approximately 7 million upper gastrointestinal (UGI) tract endoscopies are performed annually in the United States.^[2] Regular examination of mucosal and anatomical structures in diagnostic endoscopic examination is the gold standard method for the detection of malignant and premalignant lesions.^[3] By performing an evaluation in this way, it is possible to detect various pharyngeal, laryngeal and gastrointestinal precancerous or cancerous lesions at earlier stages. It is important to detect the lesions at an early stage to treat them with a minimally invasive approach, and to increase the quality of life and survival rates of the patients.^[1] The oropharynx, epiglottis, vocal cords, arytenoid cartilages, and pyriform sinuses are structures that are inevitably found in the field of view during UGI endoscopy. Therefore, this region can be examined in detail during endoscopy and many lesions in this region can be detected at an early stage.^[1]

Except for specialists dealing specifically with esophageal diseases, most UGI endoscopy physicians are not accustomed to examining the head and neck region. They generally do not fully examine the pharyngeal region, as they consider the head and neck region to be within the domain of otolaryngology specialists.^[1] The passage of the endoscope from the oral cavity and hypopharynx to the esophagus takes place at different times depending on the skill and technique of each endoscopist and is evaluated with different criteria. In practice, most laryngeal and pharyngeal (LF) zone lesions cannot be detected by endoscopists because the evaluation of the head and neck region cannot be standardized.^[1,3]

Although esophageal and head and neck cancers are rare worldwide, their incidence is increasing.^[4] On the other hand, it is very rare for otolaryngology and head and neck surgeons to detect pharyngeal cancers at an early stage.^[3,5] A recent epidemiological study showed that the majority (68%) of hypopharyngeal cancers are diagnosed at stage IV.^[6] The majority of hypopharyngeal cancers are seen in the pyriform sinus, followed by the posterior pharynx and postcricoid region. Due to its rich lymphatic structure, it spreads in the early period and can remain silent until it is detected in the advanced stage.^[7] The approach to esophageal cancers varies depending on whether there are synchronous or metachronous tumors in the LF regions.^[8]

UGI endoscopes feature high resolution imaging and magnification functions. Image quality in the hypopharyngeal area is better than flexible endoscopes. With the features

of Narrow Band Imaging (NBI) and similar imaging processes, it is possible to evaluate abnormal blood vessel structures in the mucosa in superficial or deep hypopharyngeal cancers. Hosono et al. showed that they detected pathologies of hypopharyngeal cancers at a rate of 43.7% (22/41) with the use of NBI during UGI endoscopy.^[9]

The aim of our study is to increase awareness of the identifiability of LF region lesions during UGI endoscopy, which is frequently performed in practice, to emphasize that early diagnosis of lesions in this region is important and the evaluation of LF regions should be included in the routine evaluation.

Materials and Methods

The study is designed as a cross sectional survey study. A questionnaire of 27 questions was prepared for the study. The comprehensibility of the questions was evaluated by 2 otolaryngology specialists, 2 general surgeons, and 1 gastroenterology specialist, who were not included in the study before the study. The questionnaire features various sections including demographics (4 questions), endoscopy technique and imaging time (7 questions), adequacy self-assessment (4 questions), encountering the lesion (3 questions), approaching the lesion (4 questions), and lesion identification (5 questions). Gastroenterologists and general surgeons who agreed to participate in our study and performed esophagogastroscope were asked to fill out the online questionnaire titled "Approaches of Physicians Performing UGI System Endoscopy to Hypopharyngeal and Laryngeal Lesions: Survey Study." Those who did not complete the questionnaire completely, did not approve the informed consent, and gave conflicting answers were excluded from the study.

Participants in the study were asked about their age, gender, duration of endoscopy experience, and number of monthly endoscopy. They were questioned about how long they spent in various stages of the procedure during the endoscopy of the UGI, whether they questioned the symptoms before the procedure, and whether they used the special imaging feature during the procedure. Whether the participants encountered LF lesions in their previous procedures and, if they did, their approach to the lesion was investigated. Participants in the study were asked to choose one of the options Yes/No/I am not sure in self-assessment questions of their proficiency. According to the answers, they were divided into two groups as "Yes" and "No/I'm not sure."

In the study, five normal and pathological images of the LF region, which are likely to be encountered during the UGI endoscopy procedure, were shared (Fig. 1a-e). They were asked to choose between hypopharyngeal region

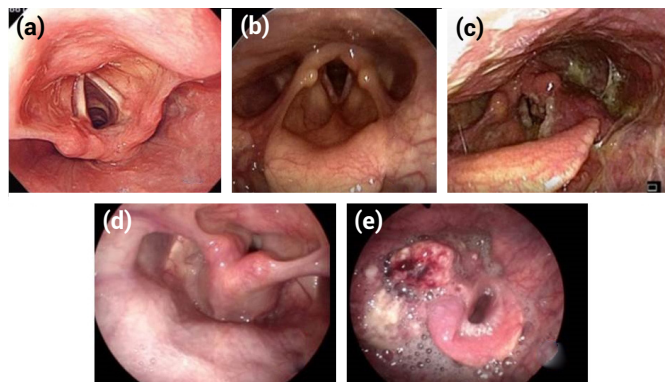


Figure 1. (a) Normal larynx (b) Suspicious lesion in the larynx (c) Larynx cancer (d) Suspicious lesion in the hypopharynx (e) Hypopharyngeal cancer.

malignancy-prediagnosed lesion, hypopharyngeal region suspicious appearance, laryngeal region malignancy-prediagnosed lesion, laryngeal region suspicious appearance, and normal hypopharyngeal-laryngeal appearance. Correct answers were given 1 point and wrong answers were given 0 point. They were divided into two groups, those with three or more correct answers and those with less than 3 correct answers. Statistical evaluation was performed between groups.

Ethical Considerations

This study was approved by the institutional ethics committee (date of approval: 14 Aug 2020, protocol number: 1354421-2020/22-5). All procedures performed in this study were compatible with the ethical standards of the institutional research committee and with those of the Declaration of Helsinki and its comparable ethical standards.

Statistical Analysis

In the descriptive statistics of the data, mean, standard deviation, median minimum, maximum, frequency and ratio values were used. Chi-square test was used in the analysis of qualitative independent data. IBM SPSS Statistics for Windows, Version 27 .0 (IBM Corp, Armonk, NY, USA) was used in the analysis.

Results

The results of 108 participants participating in the study were evaluated. Three people who did not give consent, four people who did not complete the questionnaire, and one person who gave conflicting answers were excluded from the study. Of the remaining 100 participants, 85% were male and 15% were female. According to age groups, it was observed that the participants were mostly in the age groups of 31–40 and 41–50. Survey questions and evaluation criteria are presented in Table 1.

Table 1. Survey questions and answer distributions

	n (%)
Endoscopy experience (years)	
1–3	16 (16.0%)
4–6	31 (31.0%)
7–10	24 (24.0%)
≥11	29 (29.0%)
Average endoscopy procedure time (minutes)	
0–5	35 (35.0%)
5–10	47 (47.0%)
10–15	14 (14.0%)
15–20	2 (2.0%)
≥20	2 (2.0%)
Do you perform adequate and competent diagnostic endoscopy?	
Yes	89 (89.0%)
No	2 (2.0%)
Undecided	9 (9.0%)
Do you use NBI, FICA, I-Scan in endoscopy?	
Yes, on every procedure	4 (4.0%)
Yes, sometimes	40 (40.0%)
No	12 (12.0%)
No Device Feature	44 (44.0%)
Do you question swallowing difficulty, stiffness feeling, hoarseness, smoking, alcohol use before endoscopy?	
Yes	91 (91.0%)
No	9 (9.0%)
At what stage of endoscopy do you evaluate the oral cavity, oropharynx, hypopharynx, larynx and esophagus?	
At the start of the procedure	58 (58.0%)
At the end of the procedure	42 (42.0%)
How long is the evaluation period between teeth and esophagus?	
5–20 s	68 (68.0%)
21–40 s	26 (26.0%)
41–60 s	6 (6.0%)
How long is the hypopharyngeal region evaluation period?	
1–10 s	57 (57.0%)
11–20 s	31 (31.0%)
21–40 s	9 (9.0%)
40–60 s	3 (3.0%)

Table 1. CONT.

	n (%)
Do you evaluate the laryngopharyngeal region during endoscopy?	
Yes	88 (88.0%)
No	12 (12.0%)
Are you recording images from the hypopharyngeal region?	
Yes	60 (60.0%)
No	40 (40.0%)
Do you believe you can identify lesions of the hypopharyngeal and laryngeal region?	
Yes	44 (44.0%)
No	13 (13.0%)
Undecided	43 (43.0%)
Have you encountered a hypopharyngeal lesion during endoscopy? (#)	
Yes	71 (71.0%)
No	29 (29.0%)
Have you encountered a lesion that obstructs the esophageal entrance during endoscopy? (*)	
Yes	62 (62.0%)
No	38 (38.0%)
If your answer to questions (#) and (*) is yes, how did you approach the lesion?	
I immediately terminated the procedure and referred to an otolaryngology specialist.	3 (3.9%)
After taking the image, I ended the process and referred it to an otolaryngology specialist with the endoscopy result.	35 (46.1%)
I continued the procedure by taking a biopsy.	18 (23.7%)
I continued the procedure without taking a biopsy. After the procedure, I directed him to the relevant specialist.	20 (26.3%)
Have you encountered a laryngeal region lesion during endoscopy? (‡)	
Yes	52 (52.0%)
No	48 (48.0%)
If your answer to questions (‡) is yes, how did you approach the lesion?	
I immediately terminated the procedure and referred to an otolaryngology specialist.	2 (3.8%)

Table 1. CONT.

	n (%)
After taking the image, I ended the process and referred it to an otolaryngology specialist with the endoscopy result.	24 (46.2%)
I continued the procedure by taking a biopsy.	6 (11.5%)
I continued the procedure without taking a biopsy. After the procedure, I directed him to the relevant specialist.	20 (38.5%)
What is your level of evaluation of the hypopharyngeal and laryngeal regions during endoscopy? (Good, medium, bad)	
Poor	11 (11.0%)
Moderate	63 (63.0%)
Good	26 (26.0%)
Is the training you received sufficient to evaluate hypopharyngeal lesions?	
Absolutely insufficient	4 (4.0%)
Insufficient	29 (29.0%)
Intermediate sufficient	46 (46.0%)
Sufficient	21 (21.0%)

It was observed that 71% of the participants had 10 years or less, and 29% had 11 years or more of endoscopy experience.

It has been determined that the average endoscopy procedure time is 5–10 min in 47%, 0–5 min in 35%, 10 min and more in a less rate, and the evaluation time between the teeth and esophagus is often (68%) 5–20 s, and the evaluation time of the hypopharyngeal region takes 1–10 s at a rate of 57%.

NBI, Flexible spectral Imaging Color Enhancement (FICE), Image Scan (I-Scan) in endoscopy were questioned, and it was found that 4% of the participants used these methods in each procedure, 40% occasionally used them, and 12% indicated that there is no need for use.

According to the evaluation, it was observed that the complaints of laryngeal and hypopharyngeal diseases such as difficulty in swallowing, feeling of being stuck in the throat, and hoarseness were questioned at a high rate before the endoscopy procedure (91%), and that during the endoscopy procedure, 71% of the participants encountered hypopharyngeal lesions while 62% with a lesion

that occludes the esophageal entrance, and 52% with laryngeal lesion.

When questioned how the approach would be if a lesion was encountered in these regions, about half of the participants reported that they terminated the procedure and referred to an otolaryngology physician with the lesion image. Most participants stated that they did not take biopsies from the lesions. About 60% of the participants indicated that they took logs from the hypopharyngeal region.

It was observed that LF regions were mostly evaluated (88%) during endoscopy. Participants were asked the question "Do you believe you can identify laryngeal and hypopharyngeal lesions" and 44% answered yes, while 56% answered "I'm not sure or no." It has been questioned whether UGI endoscopy training is sufficient to identify LF lesions. Scoring of 0, 1, 2, and 3 was made according to the level of proficiency. A score of 0 means completely inadequate, 1 means inadequate, 2 means moderately adequate, and 3 means completely adequate. According to these results, it was seen that 21% of the participants gave 3 points, 46% gave 2 points, 29% gave 1 point, and 4% gave 0 points.

In the questionnaire, five images containing five different lesions of the larynx and hypopharynx region were given and the participants were asked to evaluate it. Calculation was made by giving 1 point to correct answers and grouping was made according to their scores as <3 and ≥ 3 (Table 2). In the group with a score of <3 , the evaluation time between teeth and esophagus was found to be statistically significantly shorter than in the group with a score of ≥ 3 ($p<0.05$). The rate of encountering a lesion at the esophageal entrance was found to be statistically significantly higher in the group with a score of ≥ 3 ($p<0.05$). This showed that encountering a previous lesion in the hypopharyngeal region is effective in identifying LF lesions.

The identifiability of LF region lesions in the survey questions was compared statistically with other questions. Results are presented in Table 3. According to these results, the duration of endoscopy experience was found to be significantly higher in the group with identifiable lesions compared to the group with unidentified lesions ($p<0.05$). It was found that the longer the hypopharyngeal region evaluation period, the higher the identifiability of the lesions significantly in statistical

terms ($p<0.05$). The degree of evaluation of the LF region during endoscopy was found to be significantly lower in the group whose lesions of these regions could not be identified ($p<0.05$). In addition, as the inadequacy of the training received during residency increased, the identifiability of the LF region lesions was also statistically significantly lower ($p<0.05$).

Discussion

A large number of UGI endoscopy is performed each year around the world. The most common indications for UGI endoscopies include esophageal cancer screening, differential diagnosis of pharyngeal pathologies, annual follow-up cancer screenings, and pretreatment or follow-up screenings for head and neck cancers.^[10] In clinical practice, LF lesions are generally considered to be within the scope of otolaryngology diseases. In fact, it is thought that the LF region can be easily examined during UGI endoscopic procedures, but many endoscopists do not show widespread interest in these lesions and LF examination is not routinely performed.^[10] In a study conducted with 1120 patients, 39 laryngeal lesions in the LF region and leukoplakia in two of these lesions and cancer in one were detected during the GI endoscopy procedure. The study emphasized that the evaluation of the LF region during UGI is important because it makes it possible to detect cancer at an early stage.^[11]

Most of the structures that make up the larynx and hypopharynx are included in the image during UGI endoscopy.^[12] In our study, it was observed that the majority of the participants stated that they evaluated the LF region during the endoscopy procedure.

In a study performed, during an UGI endoscopy procedure for 1623 gastritis complaints, 0.12% early stage, 0.06% advanced cancer, and 0.73% benign lesions (polyps, cysts, lymphoid hyperplasia, and Zenker's diverticulum) were seen incidentally in the larynx and hypopharynx region, and it was showed that it was possible to detect cancers at an early stage.^[13] Mullhaupt et al. reported that 5% of malignant and benign lesions were detected in the LF region by endoscopists during 1311 UGI endoscopy procedures.^[10] In the first prospective study conducted on asymptomatic patients who did not have complaints such as difficulty in swallowing, a feeling of stuck in the throat, and hoarseness, various anomalies were detected in the LF region during routine UGI endoscopy.^[12] In our study, it was observed that 71% of the participants encountered

Table 2. Comparison of survey questions according to intergroup scoring

	Score<3 n (%)	Score≥3 n (%)	p
Endoscopy experience (years)			
1–3	11 (19.3%)	5 (11.6%)	0.584 χ^2
4–6	19 (33.3%)	12 (27.9%)	
7–10	12 (21.1%)	12 (27.9%)	
≥11	15 (26.3%)	14 (32.6%)	
Average endoscopy procedure time (minutes)			
0–5	22 (38.6%)	13 (30.2%)	0.891 χ^2
5–10	25 (43.9%)	22 (51.2%)	
10–15	6 (10.5%)	8 (18.6%)	
15–20	2 (3.5%)	0 (0.0%)	
≥20	2 (3.5%)	0 (0.0%)	
Do you perform adequate and competent diagnostic endoscopy?			
Yes	48 (84.2%)	41 (95.3%)	0.078 χ^2
No	2 (3.5%)	0 (0.0%)	
Undecided	7 (12.3%)	2 (4.7%)	
Do you use NBI, FICA, I-Scan in endoscopy?			
Yes on every procedure	2 (3.5%)	2 (4.7%)	0.210 χ^2
Yes sometimes	20 (35.1%)	20 (46.5%)	
No	9 (15.8%)	3 (7.0%)	
No device feature	26 (45.6%)	18 (41.9%)	
Do you question swallowing difficulty, stiffness feeling, hoarseness, smoking, alcohol use before endoscopy?			
Yes	55 (96.5%)	36 (83.7%)	0.084 χ^2
No	2 (3.5%)	7 (16.3%)	
How long is the evaluation period between teeth and esophagus?			
5–20 s	35 (81.4%)	33 (57.9%)	0.017 χ^2
21–40 s	8 (18.6%)	18 (31.6%)	
41–60 s	0 (0.0%)	6 (10.5%)	
Do you believe you can identify lesions of the hypopharyngeal and laryngeal region?			
Yes	22 (38.6%)	22 (51.2%)	0.454 χ^2
No	8 (14.0%)	5 (11.6%)	
Undecided	27 (47.4%)	16 (37.2%)	
Have you encountered a hypopharyngeal lesion during endoscopy?			
Yes	38 (66.7%)	33 (76.7%)	0.272 χ^2
No	19 (33.3%)	10 (23.3%)	
Have you encountered a lesion that obstructs the esophageal entrance during endoscopy?			
Yes	30 (52.6%)	32 (74.4%)	0.026 χ^2
No	27 (47.4%)	11 (25.6%)	

Table 2. CONT.

	Score<3 n (%)	Score≥3 n (%)	p
What is your level of evaluation of the hypopharyngeal and laryngeal regions during endoscopy? (Good, moderate, poor)			
Poor	7 (12.3%)	4 (9.3%)	0.672 χ^2
Moderate	37 (64.9%)	26 (60.5%)	
Good	13 (22.8%)	13 (30.2%)	
Is the training you received sufficient to evaluate hypopharyngeal lesions?			
Absolutely insufficient	2 (3.5%)	2 (4.7%)	0.227 χ^2
Insufficient	14 (24.6%)	15 (34.9%)	
Intermediate sufficient	31 (54.4%)	15 (34.9%)	
Sufficient	10 (17.5%)	11 (25.6%)	

χ^2 : Chi-square test.

hypopharyngeal lesions and 52% with laryngeal lesions during endoscopy.

Before the endoscopy procedure, questioning habits such as smoking, alcohol, swallowing difficulties, feeling stuck in the throat, and hoarseness are important in the approach to precancerous and cancerous lesions. However, in the endoscopy guidelines, it is seen that the question of smoking is only included in the anesthesia premedication phase.^[14] In our survey, it was seen that 91% of the participants questioned cigarette and alcohol use and the above complaints before the procedure. Before the procedure, the complaints of smoking, tobacco, alcohol use, hoarseness, hemoptysis, bad voice, odynophagia, and dysphagia should be questioned, and complaints about laryngeal and hypopharyngeal lesions should be included in the endoscopy form. Although identifying patients at risk before endoscopy emphasizes the need to perform the procedure more carefully, it should be kept in mind that precancerous and cancerous lesions can also be detected in asymptomatic cases.

Today, serious increase is observed in the incidence of esophageal and head and neck tumors.^[15] Since a serious pathology (such as early-stage cancer) is detected in one out of every 1000 endoscopy, Mullhaupt et al. reported that screening examination of the LF region should be a part of every UGI endoscopy procedure.^[10] It was emphasized that this procedure requires little time and does not require additional costs or inconvenience.^[16] For a suc-

cessful UGI endoscope procedure, the mean time to evaluate the entire system has been reported as 7–8 min in different studies.^[14] In a multicenter study, it was shown that the evaluation of the structures of the oropharynx, hypopharynx, and larynx during UGI endoscopy performed under elective conditions takes an average of 30–45 s.^[11,16,17] In our study, the evaluation time between the teeth and the esophagus was determined as 5–20 s, and the evaluation time of the hypopharyngeal region was determined as 1–10 s. The fact that the evaluation of these regions takes a short time and does not significantly extend the total procedure time allows routine evaluation of LF structures. However, the evaluation between the teeth and the esophagus should not be short, that is, expressed in seconds, and because the LF region is an integral part of UGI endoscopy, sufficient time should be allocated to this region. In our study, the fact that as the evaluation period of the interdental esophageal and hypopharyngeal regions increases, the higher identifiability of the lesions is also emphasizes the need to allocate sufficient time.

NBI (Olympus), FICE (Fujifilm), and I-Scan (Pentax) imaging systems are the imaging techniques used for endoscopic diagnostic tests in which specific blue and green wavelengths of light are used to increase the detail of certain aspects of the mucosal surfaces.^[18] While the NBI endoscope was initially used only for detailed examination of head and neck, as well as esophagus and stomach tumors, it has been shown in studies that it is routinely used in every UGI endoscopy, including the examination of the

Table 3. Comparison of the questionnaire questions according to the identifiability of the lesions.

	Yes n (%)	No+Undecided n (%)	p
Endoscopy experience (years)			
1–3	5 (11.4%)	11 (19.6%)	0.012 χ^2
4–6	12 (27.3%)	19 (33.9%)	
7–10	7 (15.9%)	17 (30.4%)	
≥ 11	20 (45.5%)	9 (16.1%)	
Average endoscopy procedure time (minutes)			
0–5	13 (29.5%)	22 (39.3%)	0.314 χ^2
5–10	25 (56.8%)	22 (39.3%)	
10–15	4 (9.1%)	10 (17.9%)	
15–20	2 (4.5%)	0 (0.0%)	
≥ 20	0 (0.0%)	2 (3.6%)	
Do you perform adequate and competent diagnostic endoscopy?			
Yes	40 (90.9%)	49 (87.5%)	0.589 χ^2
No	1 (2.3%)	1 (1.8%)	
Undecided	3 (6.8%)	6 (10.7%)	
Do you use NBI, FICA, I-Scan in endoscopy?			
Yes, on every procedure	4 (9.1%)	0 (0.0%)	0.060 χ^2
Yes, sometimes	20 (45.5%)	20 (35.7%)	
No	3 (6.8%)	9 (16.1%)	
No device feature	17 (38.6%)	27 (48.2%)	
Do you question swallowing difficulty, stiffness feeling, hoarseness, smoking, alcohol use before endoscopy?			
Yes	41 (93.2%)	50 (89.2%)	0.763 χ^2
No	3 (6.8%)	6 (10.7%)	
How long is the evaluation period between teeth and esophagus?			
5–20 s	29 (65.9%)	39 (69.6%)	0.514 χ^2
21–40 s	11 (25.0%)	15 (26.8%)	
41–60 s	4 (9.1%)	2 (3.6%)	
How long is the hypopharyngeal region evaluation period?			
1–10 s	35 (62.5%)	22 (50.0%)	0.003 χ^2
11–20 s	19 (33.9%)	12 (27.3%)	
21–40 s	1 (1.8%)	8 (18.2%)	
40–60 s	1 (1.8%)	2 (4.5%)	
What is your degree of evaluation of the hypopharyngeal and laryngeal regions during endoscopy? (Good, moderate, poor)			
Poor	1 (2.3%)	10 (17.9%)	0.000 χ^2
Moderate	21 (47.7%)	42 (75.0%)	
Good	22 (50.0%)	4 (7.1%)	

Table 3. CONT.

	Yes n (%)	No+Undecided n (%)	p
Is the training you received sufficient to evaluate hypopharyngeal lesions?			
Absolutely insufficient	0 (0.0%)	4 (7.1%)	0.001 χ^2
Insufficient	7 (15.9%)	22 (39.3%)	
Intermediate sufficient	19 (43.2%)	27 (48.2%)	
Sufficient	18 (40.9%)	3 (5.4%)	
Do you believe you can identify lesions of the hypopharyngeal and laryngeal region?			
Yes	19 (43.2%)	26 (46.4%)	0.746 χ^2
No+Undecided	25 (56.8%)	30 (53.6%)	

χ^2 : Chi-square test.

pharynx, and that pharyngeal cancers can be detected at an early stage with this method.^[19] In the study performed by Nakanishi et al., pharyngeal cancer was detected at a rate of 0.26% (29/11,050) in the examinations using NBI during UGI endoscopy, and it was reported that at least 65.8% of the detected cancerous lesions were diagnosed as superficial cancer.^[20] In our study, approximately half of the participants reported that they used one of the NBI, FICE, or I Scan features during endoscopy. About 4% use it in every transaction, while 40% use it occasionally. However, 12% stated that they did not find it necessary to use it, and 48% stated that their devices did not have these features. Since these features play an important role in early diagnosis, their routine use should be encouraged.

In various guidelines, it is recommended to log images from various localizations of the esophagus, stomach and duodenum during the procedure; however, “image logging” from the laryngopharyngeal region is not mentioned in these guidelines.^[14,21] In our study, it was observed that 60% of the participants obtained logs from the hypopharyngeal region. Since these regions are within the field of view during endoscopy and lesions can be detected in the early period, the LF region should be logged at a rate of 100% and this requirement should be included in the guidelines.

Tissue sampling from the LF region is not a preferred procedure during UGI endoscopy due to the risk of bleeding and airway obstruction.^[22] However, studies have reported that when a biopsy is taken during the procedure, there is no deterioration in the field of view after the biopsy,

the patients can tolerate it, and the procedure can be performed with sedation and local anesthesia. Therefore, it is recommended to continue the procedure after biopsy is taken from lesions seen in the head and neck region, including the pharyngeal region.^[22,23] In our study, 23.7% of those who encountered hypopharyngeal lesions stated that they had taken biopsy from these lesions. According to this result, we think that the rate of taking a biopsy is low and should be increased, drawing attention to the importance of taking a biopsy. The success of UGI endoscopy increases as experience increases.^[24] Our study also supports this fact. The identifiability of the lesions in the LF region was significantly lower in the group with less endoscopic experience.

The steps that an experienced and competent endoscopist is expected to take are included in the training program.^[24] It is also supported by the courses taken after the specialization training. In this evaluation, hypopharyngeal and laryngeal structures are not included in routine practice. As the participants in our study thought that the UGI endoscopy training they received was inadequate, the identifiability of the LF region lesions decreased significantly in statistical terms. According to this result, we predict that the identification of LF zone lesions will increase with the inclusion of these regions in the training of endoscopy evaluation of the UGI.

Depending on the technical developments in endoscopic imaging, high quality evaluation can be performed. Since there are errors in cancer diagnosis and early stage lesions are overlooked, studies have been carried out to optimize

the diagnosis of UGI diseases. These studies should be aimed at minimizing the error rates, examining the entire mucosa and encouraging the recognition of lesions.^[21] LF region analysis is not included in these studies. According to the results of our study, we suggest that the evaluation of the LF region should be routinely included in these studies and trainings. The limitations of our study are that it has a small sample size and is a survey study. However, we think that our results are valuable in order to emphasize this issue and to ensure awareness. We believe that there is a need for studies with larger participation and more sample cases.

LF lesions are generally considered to be a field of otolaryngology science, and therefore, many gastrointestinal endoscopists do not pay much attention to these lesions during endoscopic examinations of the UGI. Although cancerous and precancerous lesions of the oropharynx, hypopharynx, and larynx are rare, they can be detected incidentally at an early stage by examining these regions during routine UGI endoscopy. For this reason, pharynx and larynx structures should be among routinely evaluated regions with a holistic approach in the common UGI endoscopy practice, and LF regions should be included more in guidelines and endoscopy trainings. Since the area between the teeth and the esophagus is an integral part of the UGI, it should be possible for otolaryngology specialists to take part in the endoscopy training routinely.

Disclosures

Ethics Committee Approval: This study was approved by the institutional ethics committee (date of approval: 14 Aug 2020, protocol number: 1354421-2020/22-5).

Peer-review: Externally peer-reviewed.

Conflict of Interest: None declared.

Authorship Contributions: Concept – G.O.K., M.K.; Design – G.O.K., M.K., O.B.Ö.; Supervision – O.B.Ö.; Materials – G.O.K., M.K., M.D.; Data Collection and/or Processing – G.O.K., M.K., M.D.; Analysis and/or Interpretation – G.O.K., O.B.Ö.; Literature Search – G.O.K., M.K.; Writing – G.O.K., M.K., O.B.Ö.; Critical Review – G.O.K., O.B.Ö.

References

1. Park KS. Observable laryngopharyngeal lesions during the upper gastrointestinal endoscopy. *Clin Endosc* 2013;46:224–9.
2. Peery AF, Dellon ES, Lund J, Crockett SD, McGowan CE, Bulsiewicz WJ, et al. Burden of gastrointestinal disease in the United States: 2012 update. *Gastroenterology* 2012;143:1179–87.e3.
3. Balan GG, Sandru V, Petcu A, Constantinescu G. Incidental discovery of oro-pharyngeal cancer during routine upper gastrointestinal tract endoscopy. Is it that obvious? *Int J Med Dent* 2018;22:307–13.
4. Ferlay J, Colombet M, Soerjomataram I, Parkin DM, Piñeros M, Znaor A, et al. Cancer statistics for the year 2020: An overview. *Int J Cancer* 2021;149:778–89.
5. Emura F, Baron TH, Gralnek IM. The pharynx: examination of an area too often ignored during upper endoscopy. *Gastrointest Endosc* 2013;78:143–9.
6. Petersen JF, Timmermans AJ, van Dijk BA, Overbeek LIH, Smit LA, Hilgers FJM, et al. Trends in treatment, incidence and survival of hypopharynx cancer: a 20-year population-based study in the Netherlands. *Eur Arch Otorhinolaryngol* 2018;275:181–9.
7. Hoffman HT, Karnell LH, Shah JP, Arian S, Brown GS, Fee WE, et al. Hypopharyngeal cancer patient care evaluation. *Laryngoscope* 1997;107:1005–17.
8. Wang W-P, Ma J, Lu Q, Han Y, Li X, Jiang T, et al. Larynx-preserving limited resection with total thoracic esophagectomy and gastric pull-up reconstruction: A promising treatment for selected cervical esophageal squamous cell carcinoma. *Turk J Gastroenterol* 2020;31:948–54.
9. Hosono H, Katada C, Kano K, Kimura A, Tsutsumi S, Miyamoto S, et al. Evaluation of the usefulness of upper gastrointestinal endoscopy and the Valsalva by an otolaryngologist in patients with Hypopharyngeal cancer. *Auris Nasus Larynx* 2021;48:265–73.
10. Mullhaupt B, Jenny D, Albert S, Schmid S, Fried M. Controlled prospective evaluation of the diagnostic yield of a laryngopharyngeal screening examination during upper gastrointestinal endoscopy. *Gut* 2004;53:1232–4.
11. Lehman G, Compton M, Meadows J, Elmore M. Screening examination of the larynx and pharynx during upper gastrointestinal panendoscopy. *Gastrointest Endosc* 1982;28:176–8.
12. Katsinelos P, Kountouras J, Chatzimavroudis G, Zavos C, Beltsis A, Paroutoglou G, et al. Should inspection of the laryngopharyngeal area be part of routine upper gastrointestinal endoscopy? A prospective study. *Dig Liver Dis* 2009;41:283–8.
13. Watanabe S, Matsuda K, Arima K, Uchida Y, Nishioka M, Haruo T, et al. Detection of subclinical disorders of the hypopharynx and larynx by gastrointestinal endoscopy. *Endoscopy* 1996;28:295–8.
14. Januszewicz W, Kaminski MF. Quality indicators in diagnostic upper gastrointestinal endoscopy. *Therap Adv Gastroenterol* 2020;13:1756284820916693.
15. Ramsey T, Guo E, Svider PF, Lin H, Syeda S, Raza N, et al. Laryngeal cancer: Global socioeconomic trends in disease burden and smoking habits. *Laryngoscope* 2018;128:2039–53.
16. Raju GS. Value of screening the laryngopharyngeal area during routine upper gastrointestinal endoscopy. *Nat Clin Pract Gastroenterol Hepatol* 2005;2:22–3.
17. Huelsen A, St John AT, Pandey R, Vokes DE, McMaster JJ,

- Walmsley RS, et al. Structured oropharynx, hypopharynx and larynx assessment during routine esophagogastroduodenoscopy improves detection of pre-and early cancerous lesions: a multicenter, comparative study. *Endosc Int Open* 2021;9:154–62.
18. Gono K, Obi T, Yamaguchi M, Ohyama N, Machida H, Sano Y, et al. Appearance of enhanced tissue features in narrow-band endoscopic imaging. *J Biomed Opt* 2004;9:568–77.
19. Kumai Y, Shono T, Waki K, Murakami D, Miyamaru S, Sasaki Y, et al. Detection of hypopharyngeal cancer (Tis, T1 and T2) by ENT physicians vs gastrointestinal endoscopists. *Auris Nasus Larynx* 2020;47:135–40.
20. Nakanishi H, Doyama H, Takemura K, Yoshida N, Tsuji K, Takeda Y, et al. Detection of pharyngeal cancer in the overall population undergoing upper GI endoscopy by using narrow-band imaging: a single-center experience, 2009–2012. *Gastrointest Endosc* 2014;79:558–64.
21. Beg S, Ragunath K, Wyman A, Banks M, Trudgill N, Pritchard DM, et al. Quality standards in upper gastrointestinal endoscopy: a position statement of the British Society of Gastroenterology (BSG) and Association of Upper Gastrointestinal Surgeons of Great Britain and Ireland (AUGIS). *Gut* 2017;66:1886–99.
22. Hong HJ, Jeong S-H, Kim WS, Kim YJ. Safety of esophagogastroduodenoscopy-guided forceps biopsy and the feasibility of esophagogastroduodenoscopy for evaluation of hypopharyngeal cancer. *BMC Surg* 2019;19:105.
23. Hamada K, Ishihara R, Yamasaki Y, Akasaka T, Arao M, Iwatsubo T, et al. Transoral endoscopic examination of head and neck region. *Dig Endosc* 2018;30:516–21.
24. Forbes, N, Mohamed, R, Raman, M. Learning curve for endoscopy training: is it all about numbers?. *Best Pract Res Clin Gastroenterol.* 2016;30:349–56.