



## CASE REPORT

## Superior cluneal nerve entrapment neuropathy due to lower crossed syndrome: A case with low back pain

*Alt çapraz sendroma bağlı superior kluneal sinir tuzaklanma nöropatisi: Bel ağrılı bir olgu sunumu*

ID Hatice Rana ERDEM,<sup>1</sup> ID Fatmanur Aybala KOÇAK,<sup>2</sup> ID Emine Eda KURT,<sup>3</sup> ID Figen TUNCA<sup>2</sup>

### Summary

The superior cluneal nerve (SCN) is a sensory nerve known to be originated from the dorsal rami of the lower thoracic and lumbar nerve roots. One of the overlooked causes of low back pain (LBP) is the SCN Entrapment Neuropathy (SCNEN). SCNEN may also be associated with SCN stretching due to lumbar movement and the poor body posture through an increase in the paravertebral muscle tonus. A 59-year-old female patient presented with chronic LBP localized on the right iliac crest and radiating to the right buttock, groin, and leg. She had increased lumbar lordosis and anterior pelvic tilt. She had a tender point over the right iliac crest, and the pain was radiating to the buttock and posterolateral thigh (Tinel sign +). She was diagnosed with lower crossed syndrome and SCNEN, and a therapeutic nerve block was performed. Clinicians should consider SCNEN as a possible diagnosis of LBP.

Keywords: Low back pain; lower crossed syndrome; superior cluneal nerve block; superior cluneal nerve entrapment neuropathy.

### Özet

Süperior kluneal sinir (SKS), alt torasik ve lomber sinir köklerinin dorsal ramusundan köken alan bir duyuşal sinirdir. Bel ağrısının gözden kaçan nedenlerinden biri SKS tuzaklanma nöropatisidir. SKS tuzaklanma nöropatisi, bel hareketleri ve paravertebral kas tonus artışı sebebiyle oluşan kötü vücut postürüne bağlı SKS gerilmesi ile de ilişkilendirilebilir. Elli dokuz yaşında kadın hasta sağ iliyak krestte lokalize olan ve sağ kalça, kasık ve bacağa yayılan kronik bel ağrısıyla başvurdu. Hastanın lomber lordozu artmıştı ve anterior pelvik tilti mevcuttu. Sağ iliyak krest üzerinde hassas nokta vardı ve ağrı kalça ve posterolateral uyluğa yayılıyordu (tinel bulgusu +). Hastaya alt çapraz sendrom ve SKS tuzaklanma nöropatisi tanısı konuldu ve terapötik sinir bloku yapıldı. Klinisyenler bel ağrısı tanısında SKS tuzaklanma nöropatisini göz önünde bulundurmalarıdır.

Anahtar sözcükler: Alt çapraz sendrom; bel ağrısı; süperior kluneal sinir bloku; süperior kluneal sinir tuzaklanma nöropatisi.

### Introduction

Low back pain (LBP) is a significant health problem that can affect an individual's level of functional activity.<sup>[1]</sup> In most LBP patients, the definite cause of LBP is not clear. Extensive epidemiological studies have shown that up to 37% of patients with chronic back pain had a neuropathic component.<sup>[2,3]</sup> Superior cluneal nerve entrapment neuropathy (SCNEN) should be kept in mind as a cause of neuropathic LBP.

SCNEN around the iliac crest was first reported by Strong and Davila in 1957.<sup>[4]</sup> Several anatomical

and clinical studies are describing the LBP and leg symptoms that are caused by SCNEN.<sup>[3–9]</sup> The superior cluneal nerve (SCN) is a sensory nerve known to be originated from the dorsal rami of the lower thoracic and lumbar nerve roots. It is comprised 4–6 nerves, strolls around the paraspinal muscle, penetrates the thoracolumbar fascia near the iliac crest, and the termination of the nerve is at the buttock. A portion of the SCN-typically medial branch-follows a path through the osteofibrous tunnel formed by the thoracolumbar fascia and the iliac crest. The SCN can be trapped in this osteofibrous tunnel or at the site, where it penetrates the thoracolumbar fascia.<sup>[3–10]</sup>

<sup>1</sup>Department of Physical Medicine and Rehabilitation, Yüksek İhtisas University Faculty of Medicine, Ankara, Türkiye

<sup>2</sup>Department of Physical Medicine and Rehabilitation, Kırşehir Ahi Evran University Faculty of Medicine, Kırşehir, Türkiye

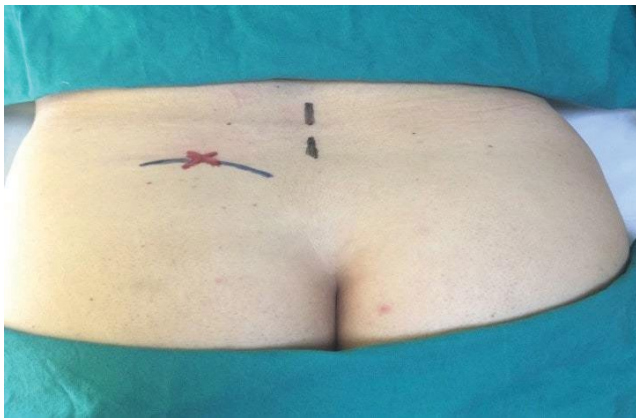
<sup>3</sup>Department of Physical Medicine and Rehabilitation, Alanya Alaaddin Keykubat University Faculty of Medicine, Antalya, Türkiye

Submitted (Başvuru): 28.01.2020 Revised (Revize): 27.02.2020 Accepted (Kabul): 23.03.2020 Available online (Online yayımlanma): 30.04.2020

**Correspondence:** Dr. Fatmanur Aybala Koçak. Kırşehir Ahi Evran Üniversitesi Tıp Fakültesi, Fiziksel Tıp ve Rehabilitasyon Anabilim Dalı, Kırşehir, Türkiye.

**Phone:** +90 - 505 - 247 07 39 **e-mail:** faybalarem@gmail.com

© 2022 Turkish Society of Algology



**Figure 1.** Trigger point over the posterior iliac crest 7 cm from the midline.

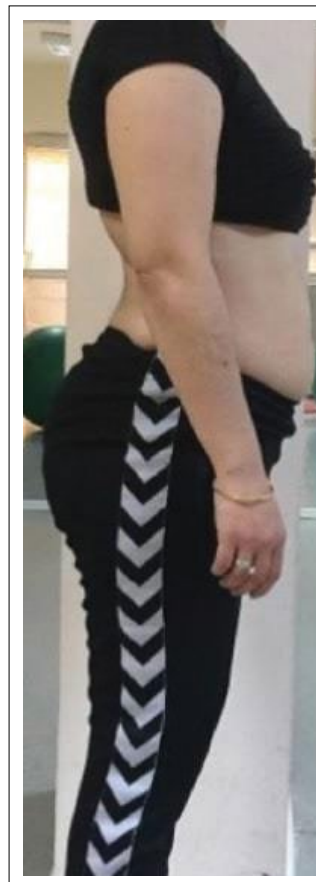
SCNEN may also be associated with SCN stretching due to lumbar movement and the body posture through an increase in the paravertebral muscle tonus.<sup>[9]</sup>

Despite severe symptoms, the diagnosis is challenging. Diagnostic criteria for SCNEN were defined.<sup>[9]</sup> The identification of the trigger point at the entrapment site (Fig. 1) and the regression of symptoms after nerve block are diagnostically important.

Since spinal surgeons and physiatrists are not sufficiently aware of the role of SCNEN in LBP, we present this case report with a review of the diagnosis and treatment of this clinical entity.

### Case Report

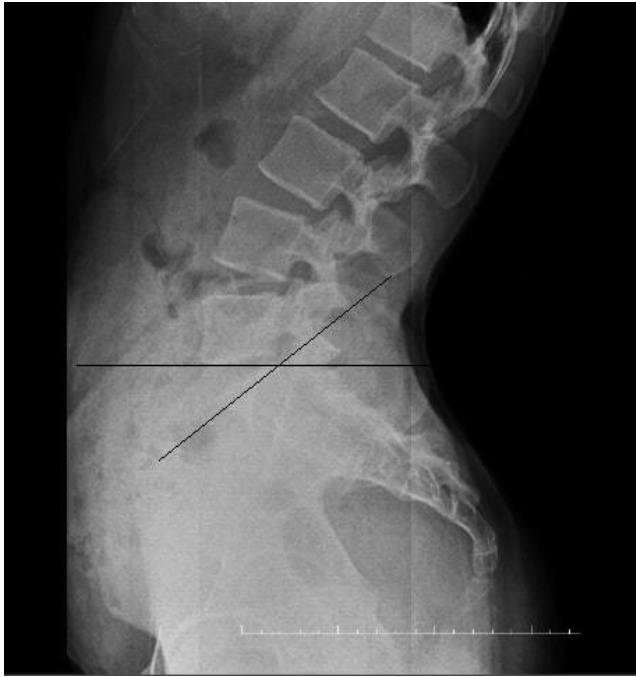Z.D., a 59-year-old female patient, also known to be a housewife, has had chronic LBP for about 10 years. For about 1 year, right hip, buttock, groin, and right leg pain have been added to the LBP. Prolonged standing, sitting, walking, turning in bed, and squatting were increasing the symptoms. Non-steroid anti-inflammatory drugs did not cause adequate relief in symptoms. In another hospital, the patient had undergone ultrasound-guided piriformis muscle injection with the diagnosis of piriformis syndrome, and the injection was repeated 6 months later. The patient also did not benefit from the injection treatments and applied to our outpatient clinic with increased complaints. A physical examination was performed. During the inspection, it was seen that the patient had increased lumbar lordosis and increased anterior pelvic tilt (Fig. 2). The range of motion of the low back and hip joints was in the normal limits, but flexion, extension, and right rotation of low back were painful. Bilateral hip flexor muscles were shortened.



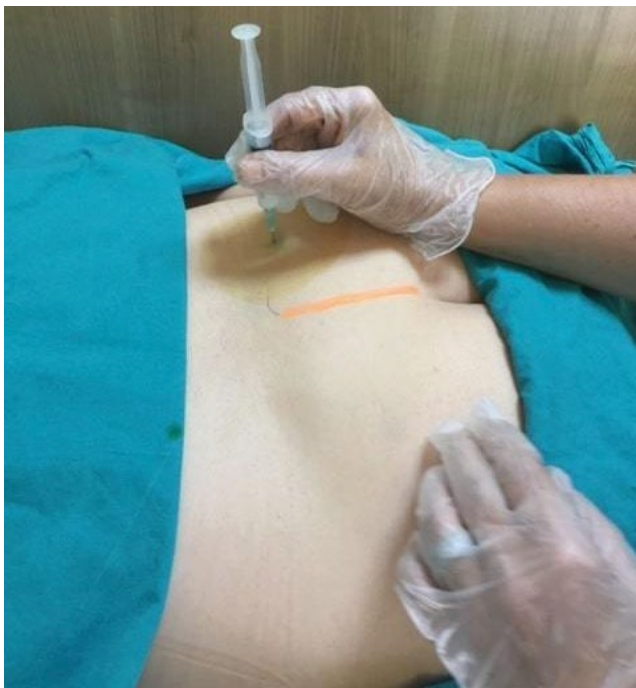**Figure 2.** Lateral inspection of the patient (increased lumbar lordosis and increased anterior pelvic tilt).

The segmental examination of the spine was regular. The straight leg raise test was negative bilaterally. The patellar tendon reflexes and the Achilles tendon reflexes were normal during the neurological examination. There was no motor, or sensory disturbance was apparent, and bowel and bladder functions were normal. She had point tenderness over the right iliac crest, which was located 7 cm laterally from the midline, and the pain was radiating to the buttock and posterolateral thigh starting from this tender point.

The patient's X-ray examination revealed no significant pathology except the increase in the sacro-horizontal angle (Fig. 3). Magnetic resonance imaging (MRI) of the lumbar spine was normal. According to the examination and imaging studies, the patient was diagnosed with lower crossed syndrome (LCS) and SCNEN. A blind SCN block was performed with 2 ml of prilocaine at the painful trigger point area. Fifteen minutes after the block, the patient's pain score decreased from 85 mm to 10 mm (0=no pain, 100=the most severe pain ever). Thus, the preliminary diagnosis was confirmed. Adhesion release maneuver was applied to the patient's painful trigger point, and cluneal nerve flossing exercises were de-



**Figure 3.** Lateral X-ray of the lumbar vertebrae of the patient.



**Figure 4.** Superior cluneal nerve block.

scribed to the patient. The pain score of the patient was 40 mm in the control examination 1 week after. The therapeutic block of SCN was applied with 40 mg methylprednisolone and 5 ml prilocaine (Fig. 4).

The patient was also taught about core stabilization exercises and stretching exercises for hip flexors and lumbar extensors for LCS. In the 1<sup>st</sup> and 3<sup>rd</sup> months of the patient's control examination, the pain was almost completely relieved.

## Discussion

SCNEN is a poorly understood clinical entity. The incidence of SCNEN in patients with LBP is unexpectedly high (1.6–14%).<sup>[6,7]</sup> Females comprise 55%–63% of all patients with SCNEN.<sup>[9]</sup> Although the average age at onset ranges between 55 and 68 years, young individuals with SCNEN have also been reported.<sup>[6,7,9,10–14]</sup>

The most common symptom of SCNEN is LBP around the iliac crest. It is exacerbated by lumbar movements involving flexion, extension, bending, rotation, prolonged standing, and walking. It produces leg symptoms in 47–84% of patients and mimics radiculopathy (pseudo-sciatica) due to lumbar disorder.<sup>[3,6,9,10,15]</sup> SCNEN also elicits intermittent claudication during walking.<sup>[9,16]</sup> The studies often report that not only flexion but also the extension of the lumbar spine aggravate the symptoms. These characteristic signs are useful as a provocative examination maneuver to scan and differentiate SCN disorders from lumbar disorders.<sup>[6]</sup> In our patient, both lumbar flexion and lumbar extension maneuver were aggravating the pain.

The proposed criteria for the diagnosis of SCNEN include unilateral or bilateral LBP involving the iliac crest and buttock, a trigger point over the posterior iliac crest located 7 cm laterally from the midline (corresponding to the nerve compression zone) and numbness and radiating pain in the SCN region (Tinel-like signs) with the compression of the trigger point.<sup>[5–7,14,15]</sup> Symptoms of relief by SCN block are essential for diagnosis.<sup>[6,9,11,17]</sup> There should also not be any pathological signs on lumbosacral radiography, computerized tomography, and magnetic resonance imaging in SCNEN. It should be considered as a cause of LBP when all other causes are ruled out.<sup>[18]</sup> Our patient fulfilled all the diagnostic criteria mentioned above. Only the sacro-horizantal angle was increased on the lumbosacral radiography, and MRI was normal.

SCNEN is often confused with facet syndrome, lumbar disk problems, or an iliolumbar syndrome since the clinical features are similar.<sup>[9,12,18,19]</sup> Episacral lipoma, which can lead to similar clinical findings and detected in similar localizations, should be kept in mind in the differential diagnosis. Episacral lipoma has a specific nodule instead of a trigger point.<sup>[20,21]</sup>

The pathogenesis of SCNEN remains unknown. The SCN can be entrapped not only in the osteofibrous tunnel in the iliac crest but also at the site where it penetrates the thoracolumbar fascia.<sup>[9,10,22,23]</sup> SCNEN has been found in the presence of diseases that are prone to increase the paravertebral muscle tonus such as Parkinson's disease and also can be seen in young athletes and soldiers who have increased muscle tonus.<sup>[12–14,24]</sup> It may be associated with an increase in the paravertebral muscle tonus with body posture and SCN stretching due to the lumbar movement.<sup>[9]</sup>

The SCN may also be susceptible to compression related to contraction of the back musculature, in particular, the thoracolumbar erector spinae (TLES) and latissimus dorsi muscles contribute to the increased pressure in the osteofibrous tunnel through, where the medial branch of the SCN runs. Several studies have linked chronic LBP with increased TLES activation and increased lumbar compressive forces.<sup>[14]</sup> In our case, the possible cause of SCNEN may be the LCS. Our patient had chronic LBP and posture disorder, which lasted for 10 years before leg pain started. The previous history of back problems of the patient would be consistent with possible increased TLES muscle activity, which may contribute to the compression of the SCN.

LCS is a muscular imbalance that includes tightness of hip flexors, lower back muscles, and weakness of abdominals, gluteus maximus muscle, also called as a distal or pelvic crossed syndrome, which alters the biomechanical force distribution in the lower back region and may lead to chronic LBP.<sup>[25,26]</sup> Janda considered muscle imbalance as an impaired relationship between muscles prone to tightness or shortness and muscles prone to inhibition. Janda noted that predominantly static or postural muscles had a tendency to contract and tighten.<sup>[27,28]</sup> We, therefore, postulate that in our case, increased tone in the muscles around the SCN due to LCS may contribute to the compression of the SCN.

The most widely accepted and first-line treatment for SCNEN is the injection over the iliac crest, 7–8 cm lateral of the midline with a local anesthetic solution. Approximately 28–100% of patients with SCNEN respond to SCN blocking.

In the current literature, visualization and assessment of the SCN with high-resolution ultrasound

have been defined.<sup>[29]</sup> There are cadaver studies and case reports in this area.<sup>[30–32]</sup> In our case, although we used the blinded method, we think that ultrasound-guided nerve imaging studies and ultrasound-guided injection methods should become widespread.

Some authors propose that SCNEN may be a manifestation of spinal ligament instability and that prolotherapy may be considered as an alternative approach in stabilizing these structures over the other treatments.<sup>[33]</sup>

In patients with SCNEN whose pain is not relieved by conservative treatment such as drugs or nerve blockage, surgical release of the entrapment may be effective.<sup>[11]</sup>

We also performed a manual soft-tissue release technique for the painful trigger point of the patient. Furthermore, cluneal nerve flossing exercises, which are the procedures aiming to restore the motion between nerves and surrounding tissues, were applied to the patient. We added stretching and core stabilization exercises to hip flexors and low back extensors in our treatment protocol for LCS, in which we think is an essential factor in chronic LBP and SCNEN.

## Conclusion

Entrapment of the SCN is thought to be an overlooked cause of LBP. The incidence of LBP due to SCNEN is unexpectedly high, and despite severe symptoms, the diagnosis can be challenging. Clinicians should be aware of this clinical entity and avoid unnecessary treatment modalities and spinal surgeries.

**Informed Consent:** *Written informed consent was obtained from the patient for the publication of the case report and the accompanying images.*

**Conflict-of-interest issues regarding the authorship or article:** *None declared.*

**Peer-review:** *Externally peer-reviewed.*

## References

1. Hoy D, March L, Brooks P, Blyth F, Woolf A, Bain C, et al. The global burden of low back pain: Estimates from the Global Burden of Disease 2010 study. *Ann Rheum Dis* 2014;73:968–74.
2. Freynhagen R, Baron R, Gockel U, Tölle TR. painDETECT: A new screening questionnaire to identify neuropathic components in patients with back pain. *Curr Med Res Opin* 2006;22:1911–20.

3. Konno T, Aota Y, Kuniya H, Saito T, Qu N, Hayashi S, et al. Anatomical etiology of "pseudo-sciatica" from superior cluneal nerve entrapment: A laboratory investigation. *J Pain Res* 2017;10:2539–45.
4. Strong EK, Davila JC. The cluneal nerve syndrome; A distinct type of low back pain. *Ind Med Surg* 1957;26:417–29.
5. Kuniya H, Aota Y, Saito T, Kamiya Y, Funakoshi K, Terayama H, et al. Anatomical study of superior cluneal nerve entrapment. *J Neurosurg Spine* 2013;19:76–80.
6. Kuniya H, Aota Y, Kawai T, Kaneko K, Konno T, Saito T. Prospective study of superior cluneal nerve disorder as a potential cause of low back pain and leg symptoms. *J Orthop Surg Res* 2014;9:139.
7. Maigne JY, Doursounian L. Entrapment neuropathy of the medial superior cluneal nerve. Nineteen cases surgically treated, with a minimum of 2 years' follow-up. *Spine (Phila Pa 1976)* 1997;22:1156–9.
8. Talu GK, Ozyalçin S, Talu U. Superior cluneal nerve entrapment. *Reg Anesth Pain Med* 2000;25:648–50.
9. Isu T, Kim K, Morimoto D, Iwamoto N. Superior and middle cluneal nerve entrapment as a cause of low back pain. *Neurospine* 2018;15:25–32.
10. Kim K, Isu T, Morimoto D, Iwamoto N, Kokubo R, Matsumoto J, et al. Common diseases mimicking lumbar disc herniation and their treatment. *Mini-invasive Surg* 2017;1:43–51.
11. Morimoto D, Isu T, Kim K, Imai T, Yamazaki K, Matsumoto R, et al. Surgical treatment of superior cluneal nerve entrapment neuropathy. *J Neurosurg Spine* 2013;19:71–5.
12. Ermis MN, Yildirim D, Durakbasa MO, Tamam C, Ermis OE. Medial superior cluneal nerve entrapment neuropathy in military personnel; Diagnosis and etiologic factors. *J Back Musculoskelet Rehabil* 2011;24:137–44.
13. Aly TA, Tanaka Y, Aizawa T, Ozawa H, Kokubun S. Medial superior cluneal nerve entrapment neuropathy in teenagers: A report of two cases. *Tohoku J Exp Med* 2002;197:229–31.
14. Speed S, Sims K, Weinrauch P. Entrapment of the medial branch of the superior cluneal nerve – a previously unrecognized cause of lower back pain in cricket fast bowlers. *J Med Cases* 2011;2:101–3.
15. Trescot AM. Cryoanalgesia in interventional pain management. *Pain Physician* 2003;6:345–60.
16. Chiba Y, Isu T, Kim K, Iwamoto N, Morimoto D, Yamazaki K, et al. Association between intermittent low-back pain and superior cluneal nerve entrapment neuropathy. *J Neurosurg Spine* 2016;24:263–7.
17. Miki K, Kim K, Isu T, Matsumoto J, Kokubo R, Isobe M, et al. Characteristics of low back pain due to superior cluneal nerve entrapment neuropathy. *Asian Spine J* 2019;13:772–8.
18. Loubsera L, Raathb RP, Van Schoora AN. Clinical anatomy of the superior cluneal nerve in relation to easily identifiable bony landmarks. *South Afr J Anaesth Analg* 2015;21:77–80.
19. Akbas M, Yegin A, Karsli B. Superior cluneal nerve entrapment eight years after decubitus surgery. *Pain Pract* 2005;5:364–6.
20. Erdem HR, Nacı B, Özeri Z, Karagöz A. Episacral lipoma: A treatable cause of low back pain. *Agri [Article in Turkish]* 2013;25:83–6.
21. Erdem HR, Nacı B. Episacral lipoma. *JPMR Sci* 2014;17:196–200.
22. Kim K, Isu T, Chiba Y, Iwamoto N, Yamazaki K, Morimoto D, et al. Treatment of low back pain in patients with vertebral compression fractures and superior cluneal nerve entrapment neuropathies. *Surg Neurol Int* 2015;6(Suppl 24):S619–21.
23. Iwamoto N, Isu T, Kim K, Chiba Y, Morimoto D, Matsumoto J, et al. Treatment of low back pain elicited by superior cluneal nerve entrapment neuropathy after lumbar fusion surgery. *Spine Surg Relat Res* 2017;1:152–7.
24. Iwamoto N, Isu T, Kim K, Chiba Y, Kokubo R, Morimoto D, et al. Low back pain caused by superior cluneal nerve entrapment neuropathy in patients with parkinson disease. *World Neurosurg* 2016;87:250–4.
25. Das S, Sarkar B, Sharma R, Mondal M, Kumar P, Sahay P. Prevalence of lower crossed syndrome in young adults: A cross sectional study. *Int J Adv Res* 2017;5:2217–28.
26. Key J. The pelvic crossed syndromes: A reflection of imbalanced function in the myofascial envelope; A further exploration of Janda's work. *J Bodyw Mov Ther* 2010;14:299–301.
27. Janda V. Muscles and motor control in low back pain: Assessment and management. In: Twomey LT, editor. *Physical therapy of the low back*. New York: Churchill Livingstone; 1987. p. 253–78.
28. Janda V. Muscle strength in relation to muscle length, pain, and muscle imbalance. In: Harms-Ringdahl K, editor. *Muscle strength. International perspectives in physical therapy* 8. Edinburgh: Churchill Livingstone; 1993. p. 83–91.
29. Chang KV, Lin CP, Lin CS, Wu WT, Karmakar MK, Özçakar L. Sonographic tracking of trunk nerves: Essential for ultrasound-guided pain management and research. *J Pain Res* 2017;10:79–88.
30. Bodner G, Platzgummer H, Meng S, Brugger PC, Gruber GM, Lieba-Samal D. Successful identification and assessment of the superior cluneal nerves with high-resolution sonography. *Pain Physician* 2016;19:197–202.
31. Ricci V, Özçakar L. Ultrasound imaging of the superior cluneal nerve: Sonoanatomy of the osteo-fibrous tunnel revisited. *Clin Anat* 2019;32:466–7.
32. Chang KV, Hsu SH, Wu WT, Özçakar L. Ultrasonographic technique for imaging and injecting the superior cluneal nerve. *Am J Phys Med Rehabil* 2017;96:e117–8.
33. Inklebarger J, Galanis N. The management of cluneal nerve referred pain with prolotherapy. *J Prolother* 2018;10:e982–91.